

# International Journal of Neurology and Neurosurgery

*Editor-in-Chief*

**Atul Goel**

Professor & HOD Dept. of Neurosurgery  
K.E.M. Hospital & Seth G. S. Medical  
College, Mumbai

*Associate Editor:*

**Trimurti D. Nadkarni**

K.E.M. Hospital & Seth G. S. Medical  
College, Mumbai

## *International Editorial Advisory Board*

**Anchal Gusain, USA**  
**Deepti Nair, USA**  
**Faiz Uddin Ahmed, USA**  
**Giuseppe Lanzino, Italy**  
**Kazuhiro Hongo, Japan**  
**Kenji Ohata, Japan**  
**Kiran K. Akula, Novato**  
**M. Necmettin Pamir, Turkey**  
**Maqsood A. Siddiqui, Saudi Arabia**  
**Sumit Sethi, Brazil**  
**Toshino Imaizumi, Japan**  
**Xiang Wang, China**  
**Yoko Kato, Japan**

## *National Editorial Advisory Board*

**Ashish Suri, New Delhi**  
**Chhavi Sharma, New delhi**  
**Kalyani Thakur, New Delhi**  
**Mamata Mishra, Bangalore**  
**Manish Jaiswal, Lucknow**  
**Rajnish Kumar Arora, Rishikesh**  
**Sachin Anil Borkar, New Delhi**  
**Sarat Chandra Yeniseti, Nagaland**  
**Sunil Kumar Singh, Lucknow**

*Managing Editor:*

**A. Lal**

*Publication Editor:*

**Manoj Kumar Singh**

© 2019 Red Flower Publication Pvt. Ltd. All rights reserved.

The views and opinions expressed are of the authors and not of the **International Journal of Neurology and Neurosurgery**. The **International Journal of Neurology and Neurosurgery** does not guarantee directly or indirectly the quality or efficacy of any product or service featured in the the advertisement in the journal, which are purely commercial.

Corresponding address  
**Red Flower Publication Pvt. Ltd.**  
48/41-42, DSIDC, Pocket-II,  
Mayur Vihar Phase-I,  
Delhi - 110 091(India)  
Phone: 91-11-22754205, 45796900,  
Fax: 91-11-22754205,  
E-mail: info@rfppl.co.in,  
Web:www.rfppl.co.in

The International Journal of Neurology and Neurosurgery (pISSN: 0975-0223, eISSN: 2455-5312) is “peer-reviewed” (refereed) journal, it is devoted to publishing papers and reports on the various aspects of neurology and neurosurgery. It is an international forum for papers of high scientific standard that are of interest to Neurologists and Neurosurgeons world-wide. Neurological progress, concerning new developments in the field of neurology and neurosurgery. The journal presents original experimental and research papers, review papers and case reports in the field of neurology and neurosurgery. The International Journal of Neurology and Neurosurgery publishes reviews and essays from eminent neurologists and neurosurgeons from around the world, as well as educational material to test your knowledge.

**Readership:** Neurologists, neurosurgeons, neuro-pathologists, neuro-psychiatrists, neuro-oncologists

**Indexing information:** The journal is indexed with & Covered by NLM catalogue & locator plus, USA; Index Copernicus, Poland; EBSCO Publishing’s Electronic Databases, USA; Academic Search Complete, USA; Academic Search Research & Development, USA; ProQuest, USA; Genamics JournalSeek, USA; OCLC World Cat.

### Subscription Information

*Institutional* (1 year)                      INR10500/USD820

#### Payment method:

By cheque:

Cheque should be in the name of **Red Flower Publication Pvt. Ltd.** payable at **Delhi**.

By Bank Transfer/TT:

1. **Complete Bank Account No.** 604320110000467
2. **Beneficiary Name (As per Bank Pass Book):** Red Flower Publication Pvt. Ltd.
3. **Address:** 41/48, DSIDC, Pocket-II, Mayur Vihar Phase-I, Delhi – 110 091(India)
4. **Bank & Branch Name:** Bank of India; Mayur Vihar
5. **Bank Address & Phone Number:** 13/14, Sri Balaji Shop, Pocket II, Mayur Vihar Phase- I, New Delhi - 110091 (India); Tel: 22750372, 22753401. **Email:** mayurvihar.newdelhi@bankofindia.co.in
6. **MICR Code:** 110013045
7. **Branch Code:** 6043
8. **IFSC Code:** BKID0006043 (used for RTGS and NEFT transactions)
9. **Swift Code:** BKIDINBBDOS
10. **Beneficiary Contact No. & E-mail ID:** 91-11-22754205, E-mail: redflowerpppl@vsnl.net

---

Send all Orders to: **Red Flower Publication Pvt. Ltd.**, 48/41-42, DSIDC, Pocket-II, Mayur Vihar Phase-I, Delhi – 110 091, India, Phone: 91-11-45796900, 22754205, 22756995, Fax: 91-11-22754205, E-mail: sales@rfpppl.co.in

# International Journal of Neurology and Neurosurgery

*Contents*

April - June 2019  
Volume 11 No. 2

## *Original Research Articles*

- Role of Decompressive Craniectomy in Acute Subdural Haematoma** 109  
I.D. Chaurasia, Jay Prakash Singour, Agam Sharma, Mahim Kosariya, Anil Kumar Gupta
- HBOT in Traumatic Brain Injury Patients: Prospective Randomized Clinical Trial** 115  
Manoj Gupta
- Awake Craniotomy: An Institutional Experience** 123  
Saranyan R., Raghavendran R.
- Evolution of Post Traumatic Acute Thin SDH into Sub acute or Chronic SDH: Analysis of Symptomatology, Risk Factor and Outcomes** 131  
R. Selvaraj, A. Agnetia Vinoth
- Diffuse Axonal Injury: An institute Experience** 137  
Swarnarekha Narayanan, Sai Sriram S., Balasubramanian D.
- Clinical Profile of Unknown Patients with Head Injuries in a Tertiary Care Centre in India: Clinical Profile and Outcome** 141  
Swarnarekha Narayanan, Krishna Narayanan M.D., Balasubramanian D.

## *Case Series*

- Case Series on Vascular Malformations Presenting as Seizures** 145  
Pradeep B., Vignesh S., Raghavendran R.
- Guidelines for Authors** 155

## Revised Rates for 2019 (Institutional)

Title of the Journal	Frequency	India(INR)		Outside India(USD)	
		Print Only	Online Only	Print Only	Online Only
Dermatology International	Semiannual	5500	5000	430	391
Gastroenterology International	Semiannual	6000	5500	469	430
Indian Journal of Anatomy	Quarterly	8500	8000	664	625
Indian Journal of Anesthesia and Analgesia	Bi-monthly	7500	7000	586	547
Indian Journal of Cancer Education and Research	Semiannual	9000	8500	703	664
Indian Journal of Communicable Diseases	Semiannual	8500	8000	664	625
Indian Journal of Dental Education	Quarterly	5500	5000	430	391
Indian Journal of Diabetes and Endocrinology	Semiannual	8000	7500	597	560
Indian Journal of Genetics and Molecular Research	Semiannual	7000	6500	547	508
Indian Journal of Hospital Administration	Semiannual	7000	6500	547	508
Indian Journal of Hospital Infection	Semiannual	12500	12000	938	901
Indian Journal of Medical & Health Sciences	Semiannual	7000	6500	547	508
Indian Journal of Pathology: Research and Practice	Bi-monthly	12000	11500	938	898
Indian Journal of Preventive Medicine	Semiannual	7000	6500	547	508
International Journal of Neurology and Neurosurgery	Quarterly	10500	10000	820	781
International Physiology	Triannual	7500	7000	586	547
Journal of Cardiovascular Medicine and Surgery	Quarterly	10000	9500	781	742
Journal of Global Medical Education and Research	Semiannual	5900	5500	440	410
Journal of Global Public Health	Semiannual	12000	11500	896	858
Journal of Microbiology and Related Research	Semiannual	8500	8000	664	625
Journal of Organ Transplantation	Semiannual	26400	25900	2063	2023
Journal of Orthopedic Education	Triannual	5500	5000	430	391
Journal of Pharmaceutical and Medicinal Chemistry	Semiannual	16500	16000	1289	1250
Journal of Practical Biochemistry and Biophysics	Semiannual	7000	6500	547	508
Journal of Radiology	Semiannual	8000	7500	625	586
New Indian Journal of Surgery	Bi-monthly	8000	7500	625	586
Ophthalmology and Allied Sciences	Triannual	6000	5500	469	430
Otolaryngology International	Semiannual	5500	5000	430	391
Pediatric Education and Research	Quarterly	7500	7000	586	547
Physiotherapy and Occupational Therapy Journal	Quarterly	9000	8500	703	664
Urology, Nephrology and Andrology International	Semiannual	7500	7000	586	547
Indian Journal of Maternal-Fetal & Neonatal Medicine	Semiannual	9500	9000	742	703
Indian Journal of Obstetrics and Gynecology	Quarterly	9500	9000	742	703
Indian Journal of Emergency Medicine	Quarterly	12500	12000	977	938
Indian Journal of Trauma and Emergency Pediatrics	Quarterly	9500	9000	742	703
Journal of Emergency and Trauma Nursing	Semiannual	5500	5000	430	391
Indian Journal of Forensic Medicine and Pathology	Quarterly	16000	15500	1250	1211
Indian Journal of Forensic Odontology	Semiannual	5500	5000	430	391
Indian Journal of Legal Medicine	Semiannual	8500	8000	664	625
International Journal of Forensic Sciences	Semiannual	10000	9500	781	742
Journal of Forensic Chemistry and Toxicology	Semiannual	9500	9000	742	703
Community and Public Health Nursing	Triannual	5500	5000	430	391
Indian Journal of Surgical Nursing	Triannual	5500	5000	430	391
International Journal of Pediatric Nursing	Triannual	5500	5000	430	391
International Journal of Practical Nursing	Triannual	5500	5000	430	391
Journal of Gerontology and Geriatric Nursing	Semiannual	5500	5000	430	391
Journal of Nurse Midwifery and Maternal Health	Triannual	5500	5000	430	391
Journal of Psychiatric Nursing	Triannual	5500	5000	430	391
Indian Journal of Ancient Medicine and Yoga	Quarterly	8000	7500	625	586
Indian Journal of Law and Human Behavior	Semiannual	6000	5500	469	430
Indian Journal of Medical Psychiatry	Semiannual	8000	7500	625	586
Indian Journal of Biology	Semiannual	5500	5000	430	391
Indian Journal of Library and Information Science	Triannual	9500	9000	742	703
Indian Journal of Research in Anthropology	Semiannual	12500	12000	977	938
Indian Journal of Waste Management	Semiannual	9500	8500	742	664
International Journal of Political Science	Semiannual	6000	5500	450	413
Journal of Social Welfare and Management	Triannual	7500	7000	586	547
International Journal of Food, Nutrition & Dietetics	Triannual	5500	5000	430	391
Journal of Animal Feed Science and Technology	Semiannual	7800	7300	609	570
Journal of Food Additives and Contaminants	Semiannual	5000	4500	391	352
Journal of Food Technology and Engineering	Semiannual	5000	4500	391	352
Indian Journal of Agriculture Business	Semiannual	5500	5000	413	375
Indian Journal of Plant and Soil	Semiannual	6500	6000	508	469

**Terms of Supply:**

- Agency discount 12.5%. Issues will be sent directly to the end user, otherwise foreign rates will be charged.
- All back volumes of all journals are available at current rates.
- All Journals are available free online with print order within the subscription period.
- All legal disputes subject to Delhi jurisdiction.
- Cancellations are not accepted orders once processed.
- Demand draft / cheque should be issued in favour of "Red Flower Publication Pvt. Ltd." payable at Delhi
- Full pre-payment is required. It can be done through online (<http://rfppl.co.in/subscribe.php?mid=7>).
- No claims will be entertained if not reported within 6 months of the publishing date.
- Orders and payments are to be sent to our office address as given above.
- Postage & Handling is included in the subscription rates.
- Subscription period is accepted on calendar year basis (i.e. Jan to Dec). However orders may be placed any time throughout the year.

**Order from**

Red Flower Publication Pvt. Ltd., 48/41-42, DSIDC, Pocket-II, Mayur Vihar Phase-I, Delhi - 110 091 (India),

Mobile: 8130750089, Phone: 91-11-45796900, 22754205, 22756995 E-mail: sales@rfppl.co.in, Website: www.rfppl.co.in

## Role of Decompressive Craniectomy in Acute Subdural Haematoma

I.D. Chaurasia<sup>1</sup>, Jay Prakash Singour<sup>2</sup>, Agam Sharma<sup>3</sup>, Mahim Kosariya<sup>4</sup>, Anil Kumar Gupta<sup>5</sup>

### Abstract

**Background:** Our aim in the present study was to assess the value of Decompressive Craniectomy in acute SDH. We sought to assess whether the surgical procedure conferred any increase in short-term survival rates. We included all patients who underwent an operation in our unit for evacuation of an AcSDH sustained as a result of trauma, It is still not clear whether early decompression can improve the outcome in severe head injury (GCS 8 or <8).

**Aim & Objectives:** The study was conducted to assess the value of decompressive craniectomy in acute SDH and to evaluate the outcome / prognostic factors and complications of decompressive craniectomy.

**Methods:** From July 2016 to April 2018, 138 patients with Acute SDH due to trauma under went for Decompressive Craniectomy. The clinical status (GCS), imaging C.T. Scan/ MRI and outcome were analyzed at Neurosurgery unit of Surgery Dept. of Hamidia Hospital which is affiliated with Gandhi Medical College, Bhopal (India). Qui square independent test and Fishers test were used to evaluate the prognostic factor.

**Result:** The study group consisted of 138 male & female, with the mean age being  $48.9 \pm 29.4$  years, ranging between 02 and 75 years. The mechanisms of injury were traffic accidents in 33 (35%); fall in 42 (45%) and blunt injury due to occupational accidents in 17 (20%) patients. Left hemispheric injury was found in 39 (42%); right hemispheric injury in 42 (45%); and bilateral hemispheric injury in 11 (13%) patients. Acute SDH was the only injury in 27 (30%) patients, while the remaining 65 (70%) had accompanying extracranial injuries.

**Conclusion:** Craniotomy can have favorable outcome in few cases of Acute SDH with unfavorable pre operative status, although craniectomy remain the standard surgical modality with pre operative poor clinical status. Early decompression in Acute SDH may be of particular benefit. The age of the patients, pupillary size and reaction at the time of admission was statistically significant predictor of outcome. Though, the indications of Decompressive Craniectomy versus Craniotomy remain a matter of debate; the Brain Trauma Foundation has identified the question of craniotomy versus decompressive craniectomy for primary evacuation of AcSDH as an vital area for further research.

**Keywords:** Traumatic Brain Injury; Decompressive Craniectomy; Acute subdural heamatoma; Outcome; Glasgow coma scale.

### How to cite this article:

I.D. Chaurasia, Jay Prakash Singour, Agam Sharma et al. Role of Decompressive Craniectomy in Acute Subdural Haematoma. Int J Neurol Neurosurg. 2019;11(2):109-113.

**Author's Affiliation:** <sup>1</sup>Associate Professor, Dept of Neurosurgery, <sup>2,3</sup>Resident <sup>4</sup>Professor, Dept. of Surgery, Gandhi Medical College, Bhopal, Madhya Pradesh 462001, India. <sup>5</sup>Staff Specialist, Dept. of Radiology, Townsville Hospital, Douglas, Australia.

**Corresponding Author:** Jay Prakash Singour, Resident, Dept. of Surgery, Gandhi Medical College, Bhopal, Madhya Pradesh 462001, India.

**E-mail:** varuny.indore09@gmail.com

**Received on** 28.01.2019, **Accepted on** 06.03.2019

### Introduction

Traumatic Acute Subdural Haematoma (SDH) continues to have high morbidity and mortality rates despite the advent of rapid transportation, computed tomography (CT) scanning, intracranial pressure monitoring and intensive care management [1,2]. Outcome for these patients may be influenced mainly by the underlying brain injury than the SDH itself [3]. decompressive craniectomy was first described by Kocher [4] and Cushing [5].

The general surgical procedure for AcSDH is craniotomy with removal of hematoma and Decompressive Craniectomy (DC) if necessary. The decision of the surgical technique depends on individual surgeon's experience in preoperative neurologic status, preoperative CT findings, and intraoperative findings. In some studies, more craniotomies than decompressive craniectomies were performed as a surgical treatment of choice for AcSDH. Even though decompressive craniectomy has its own complications and requires a subsequent cranioplasty, preemptive decompressive craniectomy can provide more effective control of intracranial pressure (ICP) and aggressive brain edema. Some patients who underwent craniotomy for removal of hematoma suffered refractory intracranial hypertension and brain edema, as a result required reoperation with decompressive craniectomy. The decompressive craniectomy showed better global outcome. The indication for decompressive craniectomy was based on clinical and radiological grounds rather than refractory intracranial pressure [5,6].

Surgical indications for AcSDH; -

- Lesion causing raised ICP
- Midline shift < 75 mm
- Brain stem compression
- Thickness of AcSDH <5 mm with midline shift.

Surgery not needed:-

- Patients with good GCS with small AcSDH.
- Patients with absent brainstem reflexes after resuscitation.

To avoid reoperation, we investigated predictable values that could indicate decompressive craniectomy. As a surgical treatment of choice by comparing groups that did and did not require reoperation using decompressive craniectomy. After craniotomy in AcSDH patients.

## Materials & Methods

In this observational study patients were analysed who had undergone decompressive craniectomy for acute SDH with 138 patients from July 2016 to April 2018 at the Neurosurgery unit of Surgery department of Hamidia Hospital & Gandhi Medical College, Bhopal. Following the establishment of airway patency and appropriate fluid resuscitation,

patients having significant acute SDH in CT were immediately operated for decompression. Data about the demographical characteristics such as age and gender, the history and clinical findings such as mechanism of injury, the time duration from the traumatic event until surgical decompression, the hemispherical location of the haematoma, the presence of extracranial injury, systolic and diastolic blood pressure, the pupillary reactivity and the signs of herniation (unilateral or bilateral pupil dilatation) were recorded. Laboratory data such as the presence of midline shift at the level of septum pellucidum in CT, complete blood count, full biochemistry and arterial blood gas measurements were also recorded at admission to the emergency department.

*Inclusion Criteria:*

1. Patients age included 02 to 75.

2. Arterial blood gas measurements included pH (normal value 7.35-7.45), partial arterial pressure of carbondioxide (PaCO<sub>2</sub>) (normal value 35-45 mmHg), partial arterial pressure of oxygen (PaO<sub>2</sub>) (normal value 80-100 mmHg), and arterial oxygen saturation (SO<sub>2</sub>) (normal value >90%).

Complete blood count tests included haemoglobin (normal value 12-18 mg/dl), white blood cell count (normal value 4800-10800/mm<sup>3</sup>) and platelet (PLT) count (normal value 130.000-400.000/mm<sup>3</sup>). Full biochemistry included blood glucose level (GLU) (normal value 70-110 mg/dl), blood urea nitrogen (BUN) (normal value 10-50 mg/dl), creatinine (CRE) (normal value 0.5-1.2 mg/dl), sodium (Na) (normal value 135-157 mEq/l), potassium (K) (normal value 3.5-5.5 mEq/l), calcium (Ca) (normal value 8.4-10.2 mEq/l), chlorine (Cl) (normal value 98-110 mEq/l), aspartate aminotransferase (AST) (normal value <40 IU.L-1), alanine aminotransferase (ALT) (normal value <40 IU.L-1), alkaline phosphatase (ALP) (Normal value 40-129 IU.L-1), gamma glutamil transferase (GGT) (Normal value <73 IU.L-1 in males; <38 IU.L-1 in females), lactate dehydrogenase (LDH) (normal value 120-146 U.L-1), creatine kinase (CK) (normal value 32-294 U.L-1 in males; 33-211 U.L-1 in females), creatine kinase-MB (CKMB) (normal value 0.6-6.3 ng/ml), total protein (Normal value 6.4-8.3 gr/dl), and albumin (normal value 3.2-4.8 gr/dl).

*Statistical Analysis*

Statistics calculated in this study, all results were calculated on SPSS 20.0 & MS Office Excel.

**Table 1:** Demographical and clinical parameters between the survivors and the non-survivors at the 30<sup>th</sup> day of the operation.

		Survivors (n = 92)	Nonsurvivors (n = 46)	p value
Age		29.6 ± 27.3	48.9 ± 29.4	0.028
Gender	Male	67 (73%)	38 (82%)	0.076
	Female	25 (27%)	08 (18%)	

**Table 2:** Clinical parameters between the survivors and the non-survivors at the 30<sup>th</sup> day of the operation.

		Survivors (n = 92) % (round figure)	Nonsurvivors (n = 46) % (round figure)	p value
Mechanism of injury	Fall	42 (45%)	17 (37%)	0.439
	TA	33 (35%)	23 (50%)	
	Occupational	17 (20%)	6 (13%)	
Time duration until surgery (hours)		5.1 ± 2.4	5.5 ± 2.5	0.701
Localisation of injury	Left hemispheric	39 (42%)	27 (58%)	0.678
	Right hemispheric	42 (45%)	11 (24%)	
	Bilateral	11 (13%)	08 (18%)	
Extracranial injury	Present	27 (30%)	14 (31%)	0.216
	Absent	65 (70%)	32 (69%)	
SAP		111.2 ± 30.1	88.5 ± 54.7	0.075
DAP		67.8 ± 22.6	51.8 ± 36.4	0.092
Pupillary reactivity		7 (3-13)	5 (3-12)	0.193
RTS		8 (4-12)	7 (1-11)	0.042
CCIS		3 (0-12)	5 (0-12) x	0.002
PLT (total/mm <sup>3</sup> X10 <sup>3</sup> )		277.3 ± 97.5	197.5 ± 102.0	0.022
GLU (mg.dl-1)		145.2 ± 51.4	266.3 ± 106.7	<0.001
BUN		29.3 ± 9.7	37.8 ± 6.5	0.005
PaO <sub>2</sub>		159.7 ± 60.5	72.0 ± 16.6	<0.001
SO <sub>2</sub>		95.9 ± 4.4	91.1 ± 4.5	0.005

## Results

Eighty two (82%) males were non-survivors where as 18% females with mean age of 48.9 in non-survivors (Table 1).

The study group consisted of 138 male & female, with the mean age being 48.9 ± 29.4 years, ranging between 02 and 75 years. The mechanisms of injury were traffic accidents in 33 (35%); fall in 42 (45%) and blunt injury due to occupational accidents in 17 (20%) patients. Left hemispheric injury was found in 39 (42%); right hemispheric injury in 42 (45%); and bilateral hemispheric injury in 11 (13%) patients. Acute SDH was the only injury in 27 (30%) patients, while the remaining 65 (70%) had accompanying extracranial injuries (Table 2).

## Discussion

This study, analyzing outcomes following traumatic evacuation in a single neurosciences

centre, shows that both CR and decompressive craniectomy are commonly used as the primary evacuation procedure. We calculated the CRASH-CT risks of mortality at 14 days and unfavourable outcome at six months and found that the population who underwent primary evacuation by decompressive craniectomy is more severely injured. However, the observed outcomes were not significantly different between the two groups.

Bone flap size is likely to play an important role in the effectiveness of decompressive craniectomy procedures. The EBIC survey investigators reported a wide variation in the dimensions of the craniectomies performed for intra-dural posttraumatic lesions. In the EBIC study, even though the mean size of decompressive craniectomy was 67 cm<sup>2</sup>, 50% of the patients who underwent emergency decompressive craniectomy for an intra-dural lesion had a bone flap size less than 60 cm<sup>2</sup>. In the present study, the average size of the bone flaps in the decompressive craniectomy. Group was 74.5 cm<sup>2</sup> and only 11% of the decompressive

craniectomy bone flaps were below 60 cm<sup>2</sup> in size. In addition, the mean maximum diameter of the bone flaps in the decompressive craniectomy group was 11.6 cm [7].

However, the major issue is that there is currently only class III evidence with retrospective studies investigating the role of decompressive craniectomy.

Our study showed poorer outcome in decompressive craniectomy group compared with Craniotomy group (poor mRS 77%, 20 of 26 patients in decompressive craniectomy group vs. 40%, 8 of 20 patients in Craniotomy group;  $p=0.004$ ). This results are may be due to more patients with low GCS score (GCS<8), unresponsive pupil, and comorbid CT lesion in decompressive craniectomy group. Our results carry similar selection bias that neurosurgeons tend to perform decompressive craniectomy. When patient's preoperative clinical status is poor. To clarify this point, we counted on number of unfavorable features for each patient that may influence on poor outcome. On average, decompressive craniectomy decompressive craniectomy group had more adverse features than Craniotomy group, and thus poor outcome for decompressive craniectomy group can be explained [8,9].

Furthermore, various possible complications of decompressive craniectomy. need awareness of neurosurgeons. Subgaleal hemorrhage, herniation through the cranial defect, subdural effusion, syndrome of the trephined (sinking skin flap syndrome), and hydrocephalus were reported complications of decompressive craniectomy [10]. In our series, 1 patient underwent reoperation due to subgaleal hematoma and 2 patients had severe sinking of skin flap where difficulty was in cranioplasty resulted in complication. decompressive craniectomy. decompressive craniectomy also have disadvantage of requiring subsequent cranioplasty which harbor additional risk of complication. Gooch et al. [11] reported that immediate post-operative complication rate of cranioplasty after decompressive craniectomy was as high as 34% which were infection, wound breakdown, intracranial hemorrhage, and bone resorption. We also experienced complications of cranioplasty in our patients (4 of 12; epidural hematoma 2, infection 1, cerebrospinal fluid leakage 1) which interrupted patient's recovery. In this context, there may be some advantage of Craniotomy in evacuation of AcSDH.

However, this study is a retrospective single center study with small patient population. Limitations

of selection bias hinder any conclusion on role of Craniotomy or decompressive craniectomy for AcSDH. We think further investigation with larger patient population and carefully selected criteria is needed to clarify the optimal surgical modality for patient with AcSDH.

## Conclusion

Craniotomy can have favorable outcome in few cases of Acute SDH with unfavorable pre operative status, although craniectomy remain the standard surgical modality with pre operative poor clinical status. Early decompression in Acute SDH may be of particular benefit. The age of the patients, pupillary size and reaction at the time of admission was statistically significant predictor of outcome. Though, the indications of Decompressive Craniectomy versus Craniotomy remain a matter of debate; the Brain Trauma Foundation has identified the question of craniotomy versus decompressive craniectomy for primary evacuation of AcSDH as an vital area for further research. The concept of performing Decompressive Craniectomy in Traumatic Acute Subdural Haematoma patients seems to be attractive.

## References

1. Servadei F. Prognostic factors in severely head injured adult patients with acute subdural haematomas. *Acta Neurochir.* 1997;139:279-85.
2. Koc RK, Akdemir H, Oktem IS, Meral M, Menku A. Acute subdural hematoma: outcome and outcome prediction. *Neurosurg Rev.* 1997;20:239-44.
3. Woertgen C, Rothoerl RD, Schebesch KM, Albert A. Comparison of craniotomy and craniectomy in patients with acute subdural haematoma. *J Clin Neurosci.* 2006;13:718-21.
4. Compagnone C, Murray GD, Teasdale GM, Maas AI, Esposito D, Princi P, et al. The management of patients with intradural post-traumatic mass lesions: a multicenter survey of current approaches to surgical management in 729 patients coordinated by the European brain injury consortium. *Neurosurgery.* 2005;57:1183-92. doi: 10.1227/01.NEU.0000186239.10915.09.
5. Cooper DJ, Rosenfeld JV, Murray L, Arabi YM, Davies AR, D'Urso P, et al. Decompressive craniectomy in diffuse traumatic brain injury. *N Engl J Med.* 2011;364:1493-1502. doi: 10.1056/NEJMoa1102077.
6. Coplin WM, Cullen NK, Policherla PN, Vinas FC, Wilseck JM, Zafonte RD, et al. Safety and feasibility of craniectomy with duraplasty as the initial surgical



- intervention for severe traumatic brain injury. *J Trauma*. 2001;50:1050-59. doi: 10.1097/00005373-200106000-00013.
7. Chaturvedi J, Botta R, Prabhuraj AR, Shukla D, Bhat DI, Devi BI. Complications of cranioplasty after decompressive craniectomy for traumatic brain injury. *Br J Neurosurg*. 2015;17:1-5.
  8. Honeybul S, Ho KM. Decompressive craniectomy for severe traumatic brain injury: the relationship between surgical complications and the prediction of an unfavourable outcome. *Injury* 2014;45: 1332-39.
  9. Yang XF, Wen L, Shen F, Li G, Lou R, Liu WG, et al. Surgical complications secondary to decompressive craniectomy in patients with a head injury: a series of 108 consecutive cases. *Acta Neurochir (Wien)* 2008;150:1241-47.
  10. Liang ES, Tipper G, Hunt L, Gan PY. Cranioplasty outcomes and associated complications: a single-centre observational study. *Br J Neurosurg*. 2016;30:122-27.
  11. Gooch MR, Gin GE, Kenning TJ, German JW. Complications of cranioplasty following decompressive craniectomy: analysis of 62 cases. *Neurosurg Focus*. 2009;26:E9.
-

## International Journal of Neurology and Neurosurgery

### Library Recommendation Form

If you would like to recommend this journal to your library, simply complete the form below and return it to us. Please type or print the information clearly. We will forward a sample copy to your library, along with this recommendation card.

#### Please send a sample copy to:

Name of Librarian

Name of Library

Address of Library

#### Recommended by:

Your Name/ Title

Department

Address

#### Dear Librarian,

I would like to recommend that your library subscribe to the International Journal of Neurology and Neurosurgery. I believe the major future uses of the journal for your library would provide:

1. useful information for members of my specialty.
2. an excellent research aid.
3. an invaluable student resource.

**I have a personal subscription and understand and appreciate the value an institutional subscription would mean to our staff.**

Should the journal you're reading right now be a part of your University or institution's library? To have a free sample sent to your librarian, simply fill out and mail this today!

Stock Manager

Red Flower Publication Pvt. Ltd.

48/41-42, DSIDC, Pocket-II

Mayur Vihar Phase-I

Delhi - 110 091(India)

Phone: 91-11-45796900, 22754205, 22756995, Cell: +91-9821671871

E-mail: sales@rfppl.co.in

## HBOT in Traumatic Brain Injury Patients: Prospective Randomized Clinical Trial

Manoj Gupta

### Abstract

**Background:** The use of hyperbaric oxygen therapy in cases with traumatic brain injury is based on the hypothesis that injured or inactive neurons would greatly benefited from increased blood flow and oxygen delivery, which later could act to metabolically or electrically may reactivate the cells.

**Objective:** To evaluate the optimal number of hyperbaric oxygen therapy sessions required in patients with head injury and to compare the neurological effects of 10, 20 and 30 sessions of hyperbaric oxygen therapy in patients with traumatic brain injury.

**Study Design:** Prospective randomized clinical trial.

**Place of Study:** The study was carried out at the Prana HBO Centre, which is owned by the Investigator and located in the Northern parts of Mumbai, in India.

**Methods:** Study was conducted over a period of 3 years and patient with Head injury referred to the Hyperbaric Unit at Prana HBO center after the initial evaluation and surgical procedure were included. Patients were randomly assigned to any of the three groups and allotted numbers were concealed to receive HBO therapy. HBO therapy was given with compressed with air at a pressure of 1.8 atmosphere absolute (ata). At this pressure the patient breathed 100% oxygen via facial mask. The HBO therapy protocol included 90 minutes oxygen breathing at 1.8 ata, 6 days a week.

**Results and Discussion:** A significant improvement in GCS scores in group H10 between the end of 10 HBOT sittings and at the end of 30<sup>th</sup> day. As well significant improvement in scores of group H20 between the end of 20 sittings and at 30<sup>th</sup> day was being observed. GOS was seen better after 20 and 30 sessions of hyperbaric oxygen therapy as compared to group I of HBOT group III showed maximum improvement in spasticity in comparisons to group I and II, however there was good improvement in spasticity all the three group. Mood swings was less in group III with only 12% patients showing mood swings, whereas in group II and group I it was around 59% and 93% respectively. Fasano carried out first clinical observation and presented a therapeutic effect of hyperbaric oxygen therapy in traumatic brain injury patients and concluded that the HBO improved the outcome following brain trauma.

**Conclusion:** Our findings shows the beneficial effects of HBO therapy in traumatic brain injury patients on GCS score, GOS, spasticity and mood swings with increase in number of multiple sessions. Despite these encouraging results further research is needed to more clearly define the mechanism and potential role of HBOT following traumatic brain injury.

**Keywords:** HBOT; Traumatic brain injury; Clinical Trial.

### How to cite this article:

Manoj Gupta. HBOT in Traumatic Brain Injury Patients: Prospective Randomized Clinical Trial. Int J Neurol Neurosurg. 2019;11(2):115-121.

**Author's Affiliation:** : Director, Prana Hyperbaric Oxygen Therapy Center, Sailee Hospital & Diagnostic Center, Prathamesh Horizon, New MHB Colony, New Link Road, Borivali West, Mumbai, Maharashtra 400091, India.

**Corresponding Author:** Manoj Gupta, Director, Prana Hyperbaric Oxygen Therapy Center, Sailee Hospital & Diagnostic Center, Prathamesh Horizon, New MHB Colony, New Link Road, Borivali West, Mumbai, Maharashtra 400091, India.

**E-mail:** [drmanojgupta222@gmail.com](mailto:drmanojgupta222@gmail.com)

**Received on** 01.03.2019, **Accepted on** 12.03.2019

### Introduction

Major cause of mortality and morbidity in young people, general population and arm force personal is trauma; mostly maximum number of deaths is being attributed to traumatic brain injury. Tremendous burden is caused by the morbidity of traumatic brain injury for both families and the society. Life saving procedures and treatment is being done such as hematoma or contusion focus

removal in traumatic brain injuries but it is observed that the prognosis is hardly being improved [1,2]. To be efficient and focused the general consensus is that the focus should be on secondary brain injury; as well major concern should be on stabilization of blood and intracranial pressure in traumatic brain injury cases. It mostly involves prompt administration of neuro-protective drugs, rehabilitative training even though the neglect of hypoxic state of brain tissue is commonly observed after traumatic brain injury.

Many researches had pointed out that secondary ischemic injury exists in brain tissue seen in very early stages of traumatic brain injury and that is being considered as important contributor to morbidity and mortality. Primary aim in general management of traumatic brain injury as such is maintenance of oxygenation and perfusion [1].

Hyperbaric oxygen therapy can be defined as breathing of hundred percent oxygen at a pressure which is higher than atmospheric pressure. In the beginning the hyperbaric oxygen therapy was being used for treatment of decompression sickness seen in divers, however over a period of time its major potential of therapy had been clearly recognized and soon got approval for majority of purposes which include in repair of wounds, anemia, thermal burns cases, delayed radiational injuries, carbon monoxide poisoning, osteomyelitis and actinomycosis etc. [3].

As apart from these general conditions, great deal of interest with hyperbaric oxygen therapy had been shown in cases with traumatic brain injury, stroke, cerebral palsy etc. The use of hyperbaric oxygen therapy in cases with traumatic brain injury is based on the hypothesis that injured or inactive neurons would greatly benefited from increased blood flow and oxygen delivery, which later could act to metabolically or electrically may reactivate the cells [4,5,6,7]. However on the contrary hyperbaric oxygen therapy is being clearly approved for the above enlisted clinical conditions and indications [8] the effects of hyperbaric oxygen therapy in relation with traumatic brain injury is yet not been clearly defined.

Hyperbaric oxygen therapy is a mode of treatment where the patient is entirely enclosed in a pressure chamber and he breathes hundred percent oxygen at a pressure which is greater than one atmosphere absolute (ATA). Hyperbaric oxygen is presently being used in an attempt to improve functional outcome following a multitude of brain injuries such as stroke, anoxic brain injury, and traumatic brain injury [9]. Number of other

authors had used various numbers of sessions of hyperbaric oxygen therapy and had shown variable results; however the frequency of hyperbaric oxygen therapy sessions in patients with head injury had not been standardized [10,11]. Grossly it appears that the clinical outcome and benefit is dependent upon the dose of hyperbaric oxygen sessions [12].

Hence in our study the aim was to evaluate the optimal number of hyperbaric oxygen therapy sessions required in patients with head injury. To accomplish the aim we laid down a prospective randomized control clinical trial with the intention to compare the neurological effects of 10, 20 and 30 sessions of hyperbaric oxygen therapy in patients with head injury.

## Patients and Methods

### *Study setting*

The study was carried out at the Prana HBO Centre, which is owned by the Investigator and located in the Northern parts of Mumbai, in India. The center has one Sechrist Monoplace hyperbaric chamber and a TCOM machine with 3 electrodes. The oxygen gas supply is from oxygen cylinders of 7000 liters' capacity each. The center has all the requisite certifications and registrations as required by the local authority in Mumbai. Study was conducted over a period of 3 years and patient with Head injury referred to the Hyperbaric Unit at Prana HBO center after the initial evaluation and surgical procedure were included. Written informed consent was obtained from the patient and patient's relative.

96 patients of age ranging from 4 years to 78 years with head injury were included in study. Patients with the history of head injury and Glasgow coma scale Score < 9 were included in the study. All patients were resuscitated and stabilized and they received neurological care according to the hospital protocol.

On receiving the patient to the HBO unit at Prana, patients were randomly assigned to any of the three groups and allotted numbers were concealed to receive HBO therapy.

Group HBOT10 (n 32): received 10 sittings of HBOT

Group HBOT20 (n 32): received 20 sittings of HBOT

Group HBOT30 (n 32) received 30 sittings of HBOT.

HBO therapy was given with compressed with air at a pressure of 1.8 atmosphere absolute (ata). At this pressure the patient breathed 100% oxygen via facial mask. The HBO therapy protocol included 90 minutes oxygen breathing at 1.8 ata, 6 days a week. ECG, non invasive automated blood pressure, respiratory rate and pulse oximeter monitoring was done during the management and therapy. Glasgow coma scale score [13] a primary outcome variable and recorded by the principal investigator after every 10 sittings and at 30 days from beginning of hyperbaric oxygen therapy in all three groups. Readings were recorded on a scale of 0 to 100 at 30 days in all three groups [14,15]. Glasgow outcome scale (GOS) in all three groups were recorded after 30 days. Modified Ashworth Scale was used to measure and grade the muscle spasticity [16].

Improvement in muscle spasticity ranging from grade 1 or more was considered to be improvement and was recorded. Tracheostomy and its removal requirement were also noted; as well the removal of Ryle's tube was also recorded. During the period of three years of trial all the patients in three groups received intensive standard of care required in traumatic brain injury and was consistent with the protocol. Whenever required surgical interventions were made.

#### *Exclusion criterion*

Patients were excluded from the trail if the patient was enrolled in another trail, pregnant, Upper respiratory tract infection, neurologic or pulmonary or otorhinolaryngologic diseases contraindicating HBO therapy.

Baseline computerized tomography (CT) scan was recorded in each case and was categorized in Cat I to Cat IV.

#### *Ethics review*

This study was performed within the scope of international ethical guidelines and legislation.

Ethics review and approval was provided by Stellenbosch University (number: U16/06/015) and the ethics committee of the Hyperbaric Society in India.

#### *Statistical Analysis*

The improvement in patients by GCS score, between all the groups is clinically significant on the basis of this assumption we set a 95% power and taking  $\alpha = 5\%$  (Level of Significance). In this study we examine total 96 patients which we divide equally in three groups randomly. We use MS Excel to analyses the statistical data, analysis data is represented by graphically and descriptive statistics calculated for different variables. Test of Significance is done by Kruskal-Wallis test & for the parametric test done through one way ANOVA. Decision of test of significance is based on p-value & it is statistically significant if p-value is less than 5% (p-value < 0.05).

#### **Results**

In the study total 96 cases were recruited, patient who fulfilled all the inclusion criteria for the study. Total 96 patients completed the study period and no patient was excluded during the study analysis 32 patients in each groups were randomized. During the period of study neither of the group patient had any episodes of cerebral oxygen toxicity nor there any adverse effects of pressurization observed. As per Table 2 all three groups were comparable with respect to demography, mode of injury and various baseline parameters. As per Table 4 neuro surgical interventions were comparable in three groups along with baseline median GCS scores. On observation the significant findings was that GCS score improved along with initiation of hyperbaric oxygen therapy. A significant improvement in GCS scores in group H10 between the end of 10 HBOT sittings and at the end of 30<sup>th</sup> day. As well significant improvement in scores of group H20 between the end of 20 sittings and at 30<sup>th</sup> day was being observed.

**Table 1:** Baseline CT categorization

Sr. No	Baseline Computerized Tomography categorization	CT Findings
1.	Cat I	No visible pathology seen on CT scan
2.	Cat II	Cisterns are present with shift 05 mm, no high or mixed density lesion >25 mL, may include bone fragments and foreign bodies.
3.	Cat III	cisterns compressed or absent, shift of 05 mm, no high or mixed density lesion >25 mL
4.	Cat IV	shift >5 mm, high or mixed density lesion >25 mL

As per Table 4 difference in the average improvement in global rating scale between group I and group II and between groups I and group III was significant, but it was comparable more significantly between group II and Group III. The GOS was seen better after 20 and 30 sessions of hyperbaric oxygen therapy as compared to group I of HBOT group III showed maximum improvement in spasticity in comparisons to group I and II, however there was good improvement in spasticity all the three group. As per Table 4 Mood

swings was less in group III with only 12% patients showing mood swings, whereas in group II and group I it was around 59% and 93% respectively. In group I, II and III seven, five and eight patients were tracheostomized respectively. At the end of 30 days of hyperbaric oxygen therapy 29% patients were decannulated in Group I as compared to 60% in group II and 50% in group III. 71% of patients Ryle's tube was removed in group I, 80% in group II and 87.5% in group III at the end of 30 days of starting of therapy.

**Table 2:** Demographic analysis of baseline parameters

Parameters		Group - I H10 (n = 32)	Group - II H20 (n = 32)	Group - III H30 (n = 32)
Age	Min. Age	4	9	7
	Average	48	45	51
	Max. Age	69	76	78
Sex Ratio		14:18	20:12	17:15
Delay in HBOT from day of Injury (Mean)		13	15	13
Patients on anticonvulsants (n)		24	25	25

**Table 3:** Patients distribution of preoperative CT category by group

Groups	Pre Operative CT Category			
	I	II	III	IV
Group - I	8	11	7	6
Group - II	2	10	9	11
Group - III	4	9	10	9

**Table 4:** GCS (E, V, M) Scores of various stages of HBOT

Sittings	Group - I H10 (n = 32)			Group - II H20 (n = 32)			Group - III H30 (n = 32)		
	E	V	M	E	V	M	E	V	M
	Baseline	3	3	5	2	4	5	3	5
At 10 days/sittings	5	5	6	4	7	6	5	7	5
At 20 days/sittings	5	5	6	4	7	7	5	7	6
At 30 days/sittings	6	5	6	5	7	7	6	7	6

**Table 5:** Improvement in patients & different parameters after 30 day of starting HBOT

Parameters		Group - I	Group - II	Group - III
Patients Improvement	Moderate	65% (0.0001)	78% (0.0001)	83% (0.0001)
	High	73% (0.0001)	85% (0.0002)	97% (0.0002)
GOS	I	16	27	24
	II	0	1	2
	III	2	0	2
	IV	9	3	4
	V	5	1	0
Patients with mood swings		93% (0.001)	59% (0.001)	12% (0.001)

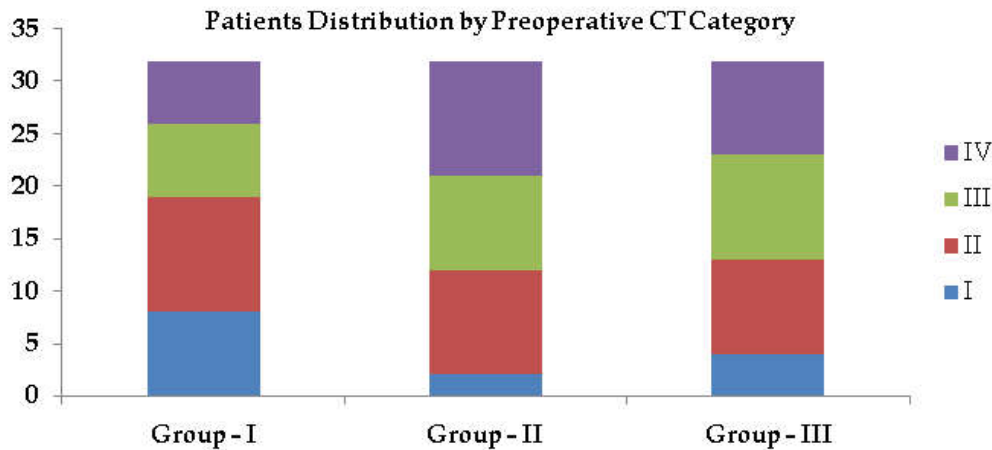


Fig. 1: Patients Distribution by Preoperative CT Category

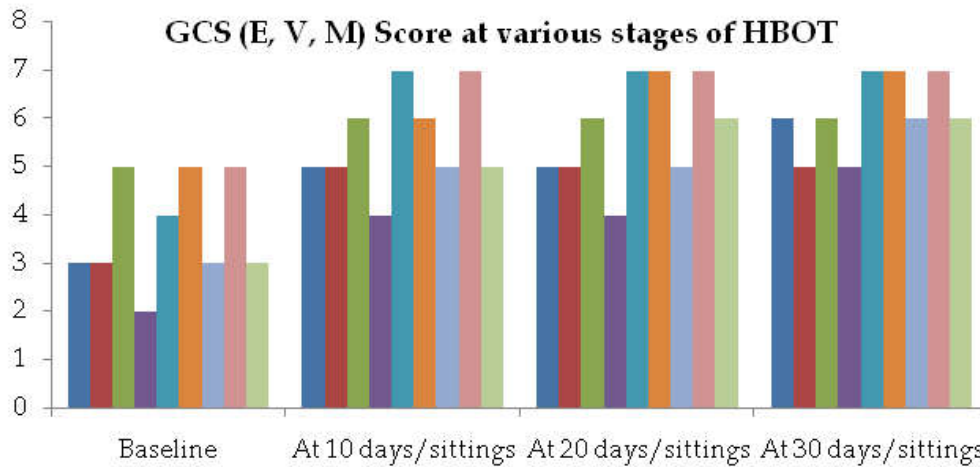


Fig. 2: GCS (E, V, M) Score at various stages of HBOT

**Discussion**

Various researchers on hyperbaric oxygen therapy in experimental traumatic brain injury have prominently clarified diverse mechanism which leads to neuro-protection in brain; mechanism includes increasing tissue oxygenation, reducing inflammation, decreasing apoptosis, reducing intra cranial pressure and promoting neurogenesis and angiogenesis. Gradually intense clinical research and trail were conducted with the aim of evaluating the efficacy and safety of hyperbaric oxygen therapy in relation with traumatic brain injuries and other neurological disorders. In clinical settings, hyperbaric oxygen therapy is usually implemented in form of repetitive sessions over extensive time periods with the aim of improving neurological outcomes after traumatic brain injury.

Usually treatment involved pressurization in a range of 1.5 to 3.0 ATA for period in between 60 to 120 minutes once or more daily with a range of less than one week to several months duration, however average being two to four weeks, mostly dependent upon the response of the patient and severity of the existing problems.

Hyperbaric oxygen therapy is an adjunctive therapy, proposed to improve an outcome in traumatic brain injury patients [17]. The mechanism by which hyperbaric oxygen therapy improves the squeal following traumatic brain injury is just a speculative. The theory is based on that damaged cells are Idling neurons in the ischemic pneumbra which have the very potential to recover [17]. However the clinical efficiency of Hyper baric oxygen Therapy in Traumatic brain injury remains controversial. Since the 1960s, many reports have

demonstrated an HBOT-associated reduction in mortalities and/or improvement of neurological functions after TBI [18]. Most are based on case studies or retrospective analyses. Standardized clinical studies reporting HBOT-associated protective effects on TBI mediated brain damage are scarce, and an explicit benefit of HBOT for TBI patients has yet to be established.

In our study we observed that the administration of hyperbaric oxygen therapy in patients with traumatic brain injury had improved the GCS score along with improvement in global rating, GOS and spasticity. This positive findings improvement gradually increased with the number of increased sittings. Mood swings were also improved with increased sessions as well de-cannulated and ryle's tube removal occurred early with increasing oxygen therapy sittings in patients with traumatic brain injury.

In 1964 Fasano et al. carried out first clinical observation and presented a therapeutic effect of hyperbaric oxygen therapy in traumatic brain injury patients and concluded that the HBO improved the outcome following brain trauma [19]. Hayakawa et al. showed that HBOT had effect in traumatic brain injury patients with change in intra cranial pressure as well reduction in CSF pressure in patients with acute cerebral damage, improved grey matter metabolic activity on single photon emission computerized tomography scan in closed head injury [18].

According to Golden et al. 2002, in chronic brain injury, ameliorated the neuropsychological disorders and enhanced neuropsychological and electrophysiological improvements [20]. Harch et al. 2009 reported to show that positive effects by improving the quality of life in patients with post concussion syndrome or mild traumatic brain injury at late chronic stage. All these studies highlighted the successful use of intensive hyperbaric oxygen therapy as therapeutic modality in various traumatic brain injury patients [21].

Apart from the positive effects of hyperbaric oxygen therapy there were concern for potential adverse effects which includes damage to ears, sinuses and lungs which are the result of pressure, temporary worsening of short-sightedness, claustrophobia and oxygen poisoning [22]. In our study prior we had an exclusion criterion; hence none of our patients had shown such complications during the course of the study. No neurological complications like seizures even though our few patients were on anticonvulsants therapy, still neurological complications were observed in few of our patients.

It is very clear from our study that the study itself had certain limitations by the fact that long term outcome of hyperbaric oxygen therapy in traumatic brain injury patients were not being evaluated. Regarding followed up regarding neuropsychiatric complications were not made. Broadly we had included all most all types of trauma to head rather than a specific group of head injury to study the multiple and increased sessions of hyperbaric oxygen therapy. There is a strong need to further more meticulous evaluation on increased multiple sessions of hyper baric oxygen therapy and concluding on ceiling effect of the multiple sessions needs to be further evaluated.

## Conclusion

In this study to conclude the impact of multiple increased session of hyperbaric oxygen therapy in traumatic brain injury patients from range of 10 to 20 sessions, outcome is favorable to traumatic brain injury patients. Our findings shows the beneficial effects of HBO therapy in traumatic brain injury patients on GCS score, GOS, spasticity and mood swings with increase in number of multiple sessions. Despite these encouraging results further research is needed to more clearly define the mechanism and potential role of HBOT following traumatic brain injury.

## Acknowledgement

Author acknowledge the immense help received from the scholars whose articles are cited and included in references of this manuscript.

*Conflict of Interest:* The author declares no conflict of interest for this study.

## References

1. Chua KS, Ng YS, Yap SG, Bok CW: A brief review of traumatic brain injury rehabilitation. *Ann Acad Med Singapore*. 2007;36:31-42.
2. Flanagan SR, Cantor JB, Ashman TA: Traumatic brain injury: future assessment tools and treatment prospects. *Neuropsychiatr Dis Treat*. 2008;4:877-92.
3. M. McDonagh, S. Carson, J. Ash et al. Hyperbaric oxygen therapy for brain injury, cerebral palsy, and stroke. Evidence report/technology assessment (Summary). 2003;85:1-6.
4. P.G. Harch, E.F. Fogarty, P.K. Staab, and K. Van Meter. Low pressure hyperbaric oxygen therapy and SPECT brain imaging in the treatment of blast-induced chronic traumatic brain injury (post-



- concussion syndrome) and post traumatic stress disorder: A case report. *Cases J.* 2009 Jun 9;2:6538.
5. R. Neubauer, S. Gottlieb, and R. Kagan. Enhancing "idling" neurons. *eLancet.* 1990;335(8688):542.
  6. A. Francis and R. Baynosa. Ischaemia-reperfusion injury and hyperbaric oxygen pathways: A review of cellular mechanisms. *Diving and Hyperbaric Medicine.* 2017;47(2):110-17.
  7. Z. Deng, W. Chen, J. Jin, J. Zhao, and H. Xu. Te neuroprotection effect of oxygen therapy: A systematic review and metaanalysis. *Nigerian Journal of Clinical Practice.* 2018;21(4):401-16.
  8. L. B. Gesell. Hyperbaric oxygen therapy indications, 2008 Committee report. Undersea and Hyperbaric Medical Society, 2008.
  9. Lin JW, Tsai JT, Lee LM, Lin CM, Hung CC, Hung KS, et al. Effect of hyperbaric oxygen on patients with traumatic brain injury. *Acta Neurochir Suppl* 2008;101:1459.
  10. Chorr V, Canini F, De Rudnicki S, Dahmani S, Gressens P, Constantin P. Hyperbaric oxygen therapy and inert gases in cerebral ischaemia and traumatic brain injury. *Ann Fr Anesth Reanim.* 2013;32:863-71.
  11. Bennett MH, Trytko B, Jonker B. Hyperbaric oxygen therapy for the adjunctive treatment of traumatic brain injury. *Cochrane Database Syst Rev* 2012;12:CD004609.
  12. Rockswold SB, Rockswold GL, Defillo A. Hyperbaric oxygen in traumatic brain injury. *Neurol Res.* 2007;29:162-72.
  13. Teasdale G, Jennett B. Assessment of coma and impaired consciousness A practical scale. *Lancet.* 1974 Jul 13;2(7872):81-4.
  14. Tsevat J, Dawson NV, Matchar DB. Assessing quality of life and preferences in the seriously ill using utility theory. *J Clin Epidemiol.* 1990;43:737.
  15. DeGuise E, leBlanc J, Feyz M, Meyer K, Duplantie J, Thomas H, et al. Longterm outcome after severe traumatic brain injury: The McGill interdisciplinary prospective study. *J Head Trauma Rehabil* 2008;23:294-303.
  16. Bohannon RW, Smith MB. Interrater reliability of a modified Ashworth Scale of muscle spasticity. *Phys Ther.* 1987 Feb;67(2):206-7.
  17. McDonough M, Helfand M, Carson S, Russman BS. Hyperbaric oxygen therapy for traumatic brain injury: A systematic review of the evidence. *Arch Phys Med Rehabil.* 2004 Jul;85(7):1198-204.
  18. Hayakawa T, Kanai N, Kuroda R, Yamada R, Mogami H. Response of cerebrospinal fluid pressure to hyperbaric oxygenation. *J Neurol Neurosurg Psychiatry.* 1971;34:580-86.
  19. Fasano VA, Nunno T, Urciolo R, Lombard G. First observation on the use of oxygen under high pressure for the treatment of traumatic coma. In: Boerema I, Brummelkamp WH, Meijne NG, eds. *Clinical application of Hyperbaric Oxygen.* Amsterdam: Elsevier. 1964.
  20. Golden Z, Golden CJ, Neubauer RA. Improving neuropsychological function after chronic brain injury with hyperbaric oxygen. *Disabil Rehabil.* 2006;28:1379-86.
  21. Harch PG, Fogarty EF, Staab PK, Van Meter K. Low pressure hyperbaric oxygen therapy and SPECT brain imaging in the treatment of blast-induced chronic traumatic brain injury (postconcussion syndrome) and post traumatic stress disorder: a case report. *Cases J.* 2009;2:6538.
  22. Plafki C, Peters P, Almeling M, Welslau W, Busch R. Complications and side effects of hyperbaric oxygen therapy. *Aviat Space Environ Med.* 2000;71:119-24.
-

## Red Flower Publication (P) Ltd.

Presents its Book Publications for sale

- |  |                      |
|--|----------------------|
| <b>1. Biostatistics Methods for Medical Research (2019)</b><br><i>by Sanjeev Sarmukaddam</i>   | <b>INR549/USD44</b>  |
| <b>2. MCQs in Medical Physiology (2019)</b> <i>by Bharati Mehta &amp; Bharti Bhandari Rathore</i>                                    | <b>INR300/USD29</b>  |
| <b>3. Synopsis of Anesthesia (2019)</b> <i>by Lalit Gupta MBBS &amp; Bhavna Gupta MBBS</i>   | <b>INR1195/USD95</b> |
| <b>4. Shipping Economics (2018)</b> <i>by D. Amutha, Ph.D.</i>   | <b>INR345/USD27</b>  |
| <b>5. Breast Cancer: Biology, Prevention and Treatment (2015)</b><br><i>by Rana P. Singh, Ph.D. &amp; A. Ramesh Rao, Ph.D. (JNU)</i> | <b>INR395/USD100</b> |
| <b>6. Child Intelligence (2005)</b> <i>by Rajesh Shukla, MD.</i>   | <b>INR150/USD50</b>  |
| <b>7. Pediatric Companion (2001)</b> <i>by Rajesh Shukla, MD.</i>  | <b>INR250/USD50</b>  |

### Order from

**Red Flower Publication Pvt. Ltd.**

48/41-42, DSIDC, Pocket-II

Mayur Vihar Phase-I

Delhi - 110 091(India)

Mobile: 8130750089, Phone: 91-11-45796900, 22754205, 22756995

E-mail: sales@rfppl.co.in

## Special Note!

Please note that our all Customers, Advertisers, Authors, Editorial Board Members and Editor-in-chief are advised to pay any type of charges against Article Processing, Editorial Board Membership Fees, Postage & Handling Charges of author copy, Purchase of Subscription, Single issue Purchase and Advertisement in any Journal directly to Red Flower Publication Pvt. Ltd.

Nobody is authorized to collect the payment on behalf of Red Flower Publication Pvt. Ltd. and company is not responsible of respective services ordered for.

## Awake Craniotomy: An Institutional Experience

Saranyan R.<sup>1</sup>, Raghavendran R.<sup>2</sup>

### Abstract

Awake Craniotomy is a Neurosurgical procedure that allows a surgeon to operate brain tumour while the patient is awake in order to preserve eloquent cerebral cortex. Surgery is done in the same way as the conventional craniotomy. This procedure is done with the aid of intra operative monitoring.

This procedure is done for the patients who have space occupying lesions in the eloquent areas, mostly commonly speech and motor area.

This study was done at The Institute of Neurosurgery, Rajiv Gandhi Government General Hospital and Madras Medical College, Chennai. For a group of patients who had tumours in the temporal and frontal lobes. All these patients were intra-operatively monitored during the procedure. The outcome of these patients re-emphasised the efficacy of this procedure in preventing significant morbidity due to the involvement of the eloquent cortex.

This study helps us to prove that, awake craniotomy with intra operative monitoring is helpful in patients with tumour in eloquent areas. It reduces post-operative morbidity in patients.

**Keywords:** Awake; Craniotomy; Eloquent; Frontal lobe; Temporal lobe.

### How to cite this article:

Saranyan R., Raghavendran R. Awake Craniotomy: An Institutional Experience. Int J Neurol Neurosurg. 2019;11(2):123-129.

### Introduction

Awake craniotomy is a novel procedure that has reduced the morbidity of the patients. The space occupying lesions present in the Frontal and Temporal lobes cause motor inactivity and speech disturbance and this leads to significant disability. This study was done to assess the reduction in

disability for the patients treated with awake craniotomy over conventional procedures. The patients from second and fifth decade were taken and the patients who were able to communicate were included in our study [1]. The patients with altered sensorium were not included in our study.

Before proceeding with awake craniotomy, anxiolytic medications were given to the patients preoperatively [2,3]. The anaesthesiologist then proceeded to administer a Scalp block. A craniotomy over the tumour region was done after fixing the patients head with a May field three pin clamp. Saline and lignocaine soaked cotton pledgets were placed over the durotomy surface to ensure dural anaesthesia and then durotomy was performed [11].

Surgery was then performed by the principle of maximal safe resection with constant clinical monitoring, when the patient starts to show signs of transient deficits in speech or motor function the resection was stopped and switched over to

**Author's Affiliation:** <sup>1</sup>Assistant Professor <sup>2</sup>Professor, Dept. of Neurosurgery, Institute of Neurosurgery, Rajiv Gandhi Government General Hospital and Madras Medical College, Chennai, Tamil Nadu 600003, India.

**Corresponding Author: Raghavendran R.,** Professor, Dept. of Neurosurgery, Institute of Neurosurgery, Rajiv Gandhi Government General Hospital and Madras Medical College, Chennai, Tamil Nadu 600003, India.

**E-mail:** [drrojaa@gmail.com](mailto:drrojaa@gmail.com)

**Received on** 08.01.2019, **Accepted on** 02.02.2019

another area that was deemed non eloquent/ non-functional [5].

## Materials and Method

The study was conducted at the Institute of Neurosurgery, Rajiv Gandhi Government General Hospital and Madras Medical College, Chennai-3.

### Inclusion Criteria

1. Age 20 to 50 yrs
2. Patients with space occupying lesion in Frontal and Temporal regions
3. Patients who are able to communicate

### Exclusion Criteria

1. Age >50 years
2. Multiple lesions
3. GCS <12
4. Patients who were not operated earlier
5. Hemodynamic instability
6. Patients with anxiety disorders, schizophrenia, claustrophobia
7. Patients with low pain tolerance
8. Patient who developed seizure during the procedure excluded from the study

### Procedure

This is a prospective descriptive study in which 20 consecutive patients underwent awake craniotomy for lesions within the eloquent cortex, who did not have a diminution of consciousness at presentation and tolerated the procedure (physically and psychologically). The decision regarding awake craniotomy was made by both the anaesthetist and surgeon [1-10]. Patient planned for awake craniotomy underwent thorough pre-operative clinical assessment and risk evaluation of surgical intervention under awake anaesthesia [15,53]. The details of the surgery and theatre environment including instruments and staff were shown and explained to the patients [12-17]. As soon as the patient arrived in the operating theatre, two wide bore intravenous canulae were inserted for fluid and medications and standard monitoring was applied [21].

Sedation was started using Dexmedetomidine [33-38] and head was stabilised in proper position with Mayfield. Skin incision was made accordingly [18,51]. Oxygen was supplemented

through a nasal cannula and a urinary catheter was inserted.

Patients were then placed supine and the head of the patient was fixed with Mayfield frame position and turned to one side with a sand bag under the shoulder [52]. The patient was supported with soft pillows to provide maximal intra-operative comfort. Draping was done in such a way that eye contact could be maintained with the patient for assessment and for the airway if emergency airway management was needed [22-28]. A set of laryngeal mask airway was prepared to be used if airway obstruction developed intra-operatively [40,41,42]. Skin and bone flap were made following scalp block by blocking supraorbital, supratrochlear, auriculotemporal, zygomaticotemporal, posterior auricular branches of greater auricular nerve, greater, lesser and third occipital nerves [48,49]. Bupivacaine without adrenaline was selected as most of the selected candidates were elderly and with cardiovascular diseases. Following elevation of bone flap, the Dura was installed with 5 ml of 2% Lignocaine before incision [46,47] and the intravenous sedation was then tailored down to facilitate functional assessment [18,19,23-25,50]. The tumour was resected slowly, during the resection the patient was encouraged to continue speaking as well as to move his/her limbs and this clinical status of the patient was constantly monitored [43,44,45]. A sluggish response or an alteration of response was judged to be due to the presence of eloquent cortex and the resection was stopped. In this way most of the tumour is resected and the tissue was sent for histo-pathological examination to check the grade of the tumour. Sedation was restarted upon closure of dura and was terminated at the end of skin closure. Verbal communication was continuously maintained with the patient to assess the speech while hand and foot movements were also monitored [16]. After Checking on the grade of the tumour the patient was subjected to radiotherapy for completion of the treatment [18-21].

## Results

### Patient demographics

Patient demographics are as those depicted in Table 1, there was no predilection for age or sex.

**Table 1:** Patient demographics

Age	Male	Female
20 - 30	4	4
30-40	4	3
40 - 50	3	2

**Table 2:** Post-operative deficit

	No. of patients with Hemiparesis (% of total)	No. of patients with Aphasia (% of total)
POD 1	8 (40%)	9 (45%)
POD 3	5 (25%)	3 (15%)
POD 5	2 (10%)	3 (15%)
POD 7	2 (10%)	1 (5%)

The patients who underwent craniotomy for eloquent cortex lesions by this method had a favourable post-operative morbidity profile in terms of fixed neurological deficit (motor and language) compared to conventional case series of patients undergoing craniotomy for the same. As described in table 2, the number of patients with hemiparesis was 8 (around 40% of patients) however by POD 7 only 2 patients had hemiparesis, whereas around 9 patients (45%) had post-operative aphasia, this aphasia subsequently improved in 8 patients and by POD 7 only 1 patient had documented aphasia.

The general complications for craniotomy were comparable to those patients undergoing conventional craniotomy.

*Statistical Analysis*

Age * Gender Cross tabulation				
Count				
	Age	Gender		Total
		Female	Male	
	20 - 30	4	4	8
	30 - 40	3	4	7
	40 - 50	2	3	5
	Total	9	11	20

Chi-Square Tests			
	Value	df	Asymp. Sig. (2-sided)
Pearson Chi-Square	.144a	2	.930
Likelihood Ratio	.144	2	.930
N of Valid Cases	20		

a. 6 cells (100.0%) have expected count less than 5. The minimum expected count is 2.25.

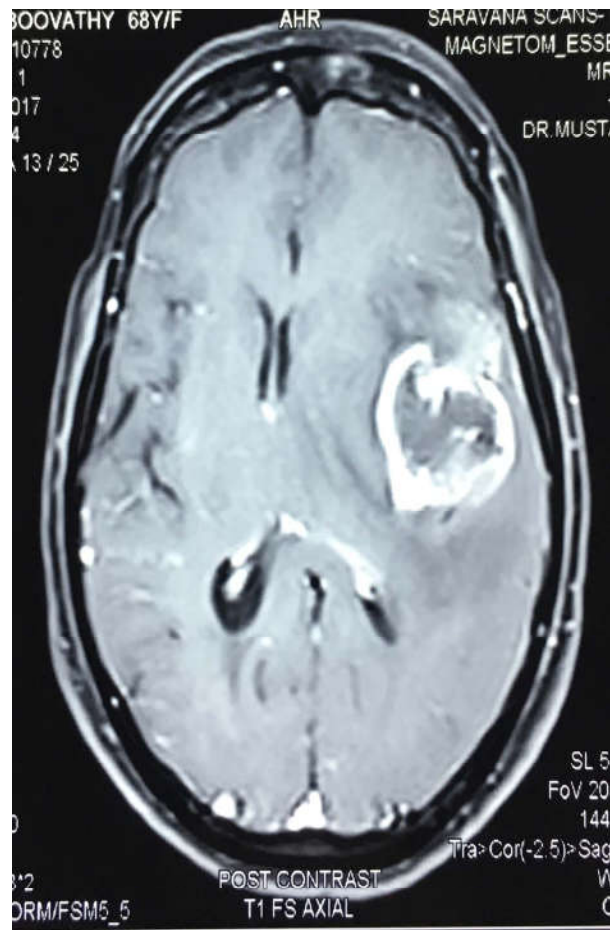
POD * Outcome Cross tabulation				
Count				
POD		Outcome		Total
		Aphasia	Hemi paresis	
POD 1	9	8	17	
POD 3	3	5	8	
POD 5	3	2	5	
POD 7	1	2	3	
Total	16	17	33	

Chi-Square Tests			
	Value	df	Asymp. Sig. (2-sided)
Pearson Chi-Square	1.063a	3	.786
Likelihood Ratio	1.075	3	.783
No. of Valid Cases	33		

a. 6 cells (75.0%) have expected count less than 5. The minimum expected count is 1.45.

The collected data were analysed with IBM. SPSS statistics software 23.0 Version. To describe about the data descriptive statistics frequency analysis, percentage analysis were used. To find the significance in categorical data Chi-Square test was used. In the above statistical tool the probability value .05 is considered as significant level.

p -Value # No Significant at p >.050



**Fig. 1:**

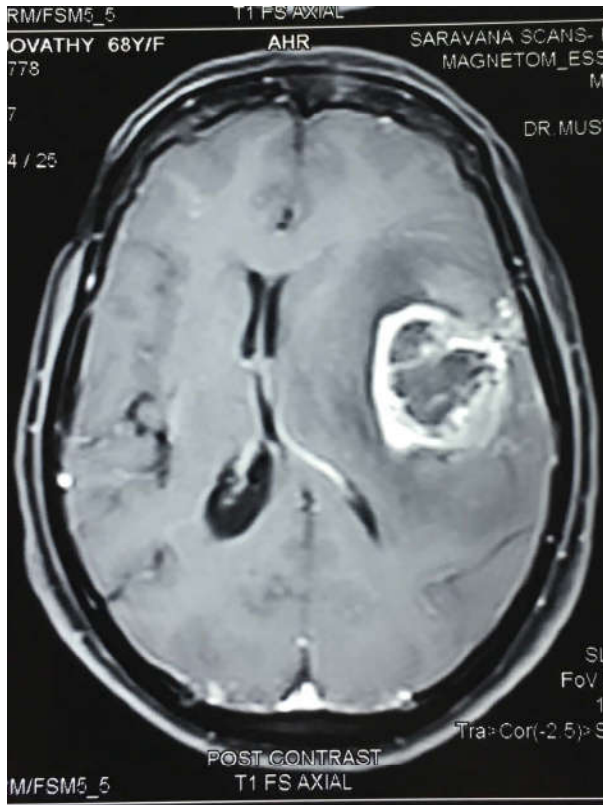


Fig. 2:

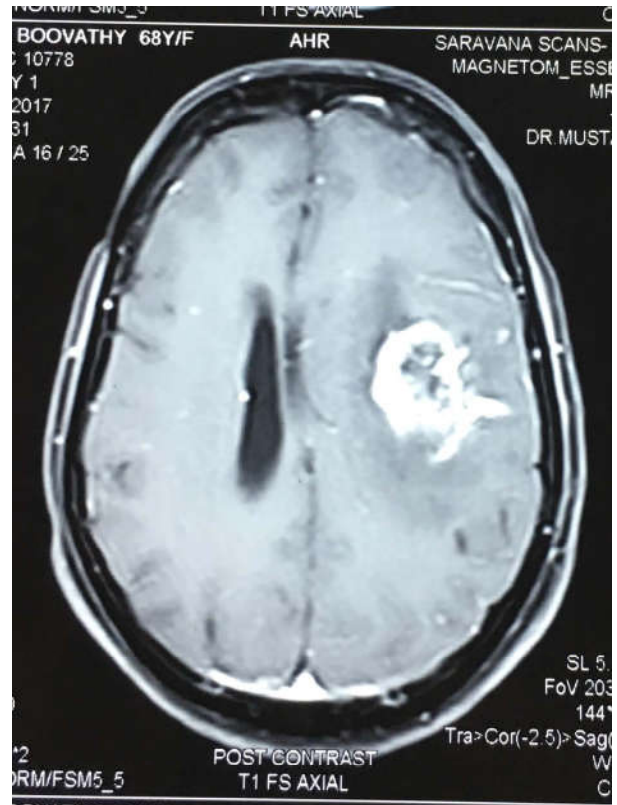


Fig. 4:

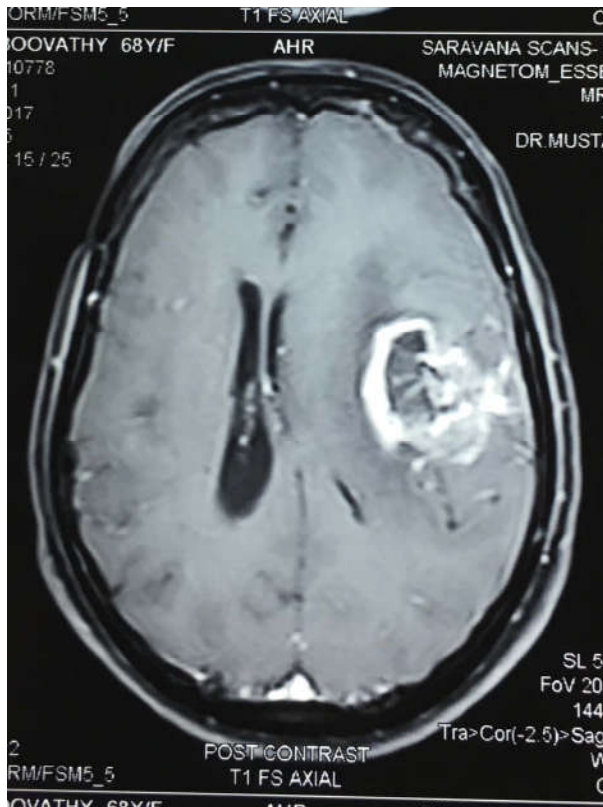

Fig. 3:

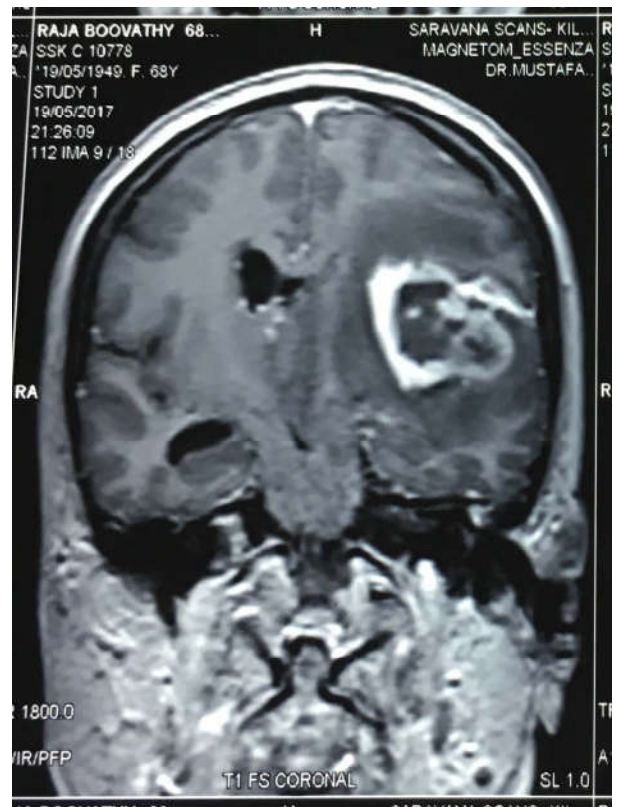

Fig. 5:

## Discussion

### *Frontal Lobe*

It is situated in the anterior and centre part of the brain and present in both the hemispheres. It controls the motor and sensory activities of the body. They represent the motor and sensory homunculus of the body. Any space occupying lesion in that area causes compression of the motor cortex or the sensory cortex and produces motor paresis or sensory loss.

### *Temporal Lobe*

It is situated on both sides of the brain, just above the ear. The main functions of the temporal lobe are speech, comprehension, memory and emotional responses. Any type of injury or compression by the space occupying lesions over the temporal lobe causes difficulty in speaking or comprehension.

### *Glioma*

It usually arises from ependymal cells, astrocytes and oligodendrocytes. They are of two types Low grade and High grade Glioma. The Low grade is well differentiated and carry good prognosis for the patient and the recurrences rate is less. The High grade is poorly differentiated and carry poor prognosis. The recurrence rate is high. The patient might need radiotherapy.

Awake craniotomy requires an adequate level of sedation during the opening and closure of bone flap without producing respiratory depression, full consciousness during the stage of removal of tumour maximum comfort of patient throughout the procedure. The common target for all techniques is to facilitate maximum possible tumour resection while sparing normal brain functions. Specific data analysis of patients revealed a significantly better neurological outcome and quality of resection in the awake craniotomy group than the group of general anaesthesia with conventional patients with lesions in eloquent areas. Craniotomy and resection of space occupying lesion usually takes more than 5 hours. Such lengthy operation time mandates a degree of sedation that should be titrated in such a way that the patient remains comfortable, motionless, alert and cooperative during resection of space occupying lesion and neurological assessment.

Although the operation time was not in favour of an awake patient to stay motionless and comfortable throughout the procedure, adherence to details of the ideal awake craniotomy technique helped to prevent these events. Skin incision and craniotomy are the most painful phases of this operation. A rapid

control and modulation of sedation and analgesia is absolutely mandatory to manage painful surgical stimuli. The success of surgery largely depends on adequate scalp block; otherwise patients may become restless and uncooperative, requiring higher doses of analgesics or sedatives which can interfere with functional assessment and airway patency. Bupivacaine 0.5% combined with adrenaline 1:200,000 may be used to carry out the block.

After the tumour has been removed, all bleeding is stopped and the dura (thick membrane surrounding the brain) is closed with sutures. The bone flap is replaced with three titanium, mini-plates and screws. Then scalp is closed. The skin is then closed with staples and the wound is dressed and a head bandage is applied.

Post-operative recovery is usually much quicker than with a conventional craniotomy. Patient advised to take oral diet and mobilised as soon as possible and also able to be discharge the patient as soon as possible than compared to conventional craniotomy.

Risk of awake craniotomy for a brain tumour is the same as those for conventional craniotomy. A small risk of seizures during surgery in such cases it is required to convert into general anaesthetic. But overall complications following awake craniotomy are uncommon and the degree of risk depends on a number of factors such as the age, co-morbidities, size, location and type of the tumour.

Following are the some of the expected complications of awake craniotomy but not exclusive in all patients.

- Neurological deficit such paralysis of limbs or aphasia
- Haematoma in the tumour bed
- Brain oedema
- Brain abscess and wound infection
- Development of seizures
- CSF leak from the wound site.

## Conclusion

Though 8 patients had transient motor weakness and 9 patients had transient speech disturbances, there was significant improvement in the post-operative period. Only 2 patients had persistent motor weakness and one had aphasia on 7<sup>th</sup> postoperative POD. Hence we conclude Awake Craniotomy is a safe procedure in patients with tumors involving eloquent areas of the brain.

## References

1. Klimek M, Verbrugge SJ, Roubos S, et al. Awake craniotomy for glioblastoma in a 9-year-old child. *Anaesthesia*. 2004;59:607-09.
2. Manninen PH, Tan TK. Postoperative nausea and vomiting after craniotomy for tumor surgery: a comparison between awake craniotomy and general anesthesia. *J ClinAnesth*. 2002;14:279-83.
3. Serletis D, Bernstein M. Prospective study of awake craniotomy used routinely and nonselectively for supratentorial tumors. *J Neurosurg*. 2007;107:1-6.
4. Blanshard HJ, Chung F, Manninen PH, et al. Awake craniotomy for removal of intracranial tumor: considerations for early discharge. *AnesthAnal* 2001;92:89-94.
5. Bonhomme V, Born JD, Hans P. Anaesthetic management of awake craniotomy. *Ann FrAnesth Reanim*. 2004;23:389-94.
6. Conte V, Baratta P, Tomaselli P, et al. Awake neurosurgery: an update. *Minerva Anestesiol*. 2008; 74:289-92.
7. Bulsara KR, Johnson J, Villavicencio AT. Improvements in brain tumor surgery: the modern history of awake craniotomies. *Neurosurg Focus* 2005;18:e5.
8. Hans P, Bonhomme V. Anesthetic management for neurosurgery in awake patients. *Minerva Anestesiol* 2007;73:507-512.
9. Kalenka A, Schwarz A. Anaesthesia and Parkinson's disease: how to manage with new therapies? *Curr Opin Anaesthesiol*. 2009;22:419-24.
10. Hol JW, Klimek M, van dH-M, et al. Awake craniotomy induces fewer changes in the plasma amino acid profile than craniotomy under general anesthesia. *J NeurosurgAnesthesiol*. 2009;21:98-107.
11. Lanier WL. Brain tumor resection in the awake patient. *Mayo ClinProc*. 2001;76:670-72.
12. MaertensdN, Born JD, Hans P, et al. Intraoperative localisation of the primary motor cortex using single electrical stimuli. *J NeurolNeurosurg Psychiatry* 1996;60:442-44.
13. Kim SS, McCutcheon IE, Suki D, et al. Awake craniotomy for brain tumors near eloquent cortex: correlation of intraoperative cortical mapping with neurological outcomes in 309 consecutive patients. *Neurosurgery*. 2009;64:836-45.
14. Picht T, Kombos T, Gramm HJ, et al. Multimodal protocol for awake craniotomy in language cortex tumour surgery. *ActaNeurochir (Wien)*. 2006; 148:127-37.
15. Chung F, Yegneswaran B, Liao P, et al. STOP questionnaire: a tool to screen patients for obstructive sleep apnea. *Anesthesiology* 2008; 108:812-21.
16. Signorelli F, Guyotat J, Isnard J, et al. The value of cortical stimulation applied to the surgery of malignant gliomas in language areas. *NeuroSci* 2001;22:3-10.
17. Whittle IR, Midgley S, Georges H, et al. Patient perceptions of 'awake' brain tumour surgery. *ActaNeurochir (Wien)*. 2005;147:275-77.
18. Hans P, Bonhomme V, Born JD, et al. Target-controlled infusion of propofol and remifentanil combined with bispectral index monitoring for awake craniotomy. *Anaesthesia*. 2000;55:255-59.
19. Berkenstadt H, Perel A, Hadani M, et al. Monitored anesthesia care using remifentanil and propofol for awake craniotomy. *J NeurosurgAnesthesiol* 2001; 13:246-49.
20. Gignac E, Manninen PH, Gelb AW. Comparison of fentanyl, sufentanil and alfentanil during awake craniotomy for epilepsy. *Can J Anaesth*. 1993; 40:421-24.
21. Tobias JD, Jimenez DF. Anaesthetic management during awake craniotomy in a 12-year-old boy. *PaediatrAnaesth* 1997;7:341-44.
22. Sarang A, Dinsmore J. Anaesthesia for awake craniotomy - evolution of a technique that facilitates awake neurological testing. *Br J Anaesth* 2003;90:161-65.
23. Keifer JC, Dentchev D, Little K, et al. A retrospective analysis of a remifentanil/propofol general anesthetic for craniotomy before awake functional brain mapping. *Anesth Analg*. 2005;101:502-08.
24. Lobo F, Beiras A. Propofol and remifentanil effect-site concentrations estimated by pharmacokinetic simulation and bispectral index monitoring during craniotomy with intraoperative awakening for brain tumor resection. *J Neurosurg Anesthesiol* 2007;19:183-89.
25. Johnson KB, Egan TD. Remifentanil and propofol combination for awake craniotomy: case report with pharmacokinetic simulations. *J Neurosurg Anesthesiol*. 1998;10:25-29.
26. Manninen PH, Balki M, Lukitto K, Bernstein M. Patient satisfaction with awake craniotomy for tumor surgery: a comparison of remifentanil and fentanyl in conjunction with propofol. *AnesthAnal* 2006;102:237-42.
27. Stricker PA, Kraemer FW, Ganesh A. Severe remifentanil-induced acute opioid tolerance following awake craniotomy in an adolescent. *J ClinAnesth*. 2009;21:124-26.
28. Herrick IA, Craen RA, Gelb AW, et al. Propofol sedation during awake craniotomy for seizures: patient-controlled administration versus neurolept analgesia. *AnesthAnal*. 1997;84:1285-1291.
29. Frost EA, Booij LH. Anesthesia in the patient for awake craniotomy. *Curr Opin Anaesthesiol*. 2007; 20:331-35.



30. Rath GP, Prabhakar H. Spectral entropy monitoring in a patient undergoing awake craniotomy. *J Neurosurg Anesthesiol.* 2007;19:144.
  31. Soriano SG, Eldredge EA, Wang FK, et al. The effect of propofol on intraoperative electrocorticography and cortical stimulation during awake craniotomies in children. *Paediatr Anaesth.* 2000;10:29-34.
  32. Herrick IA, Craen RA, Gelb AW, et al. Propofol sedation during awake craniotomy for seizures: electrocorticographic and epileptogenic effects. *Anesth Analg.* 1997;84:1280-84.
  33. Bhana N, Goa KL, McClellan KJ. Dexmedetomidine. *Drugs.* 2000;59:263-68.
  34. Mack PF, Perrine K, Kobylarz E, et al. Dexmedetomidine and neurocognitive testing in awake craniotomy. *J Neurosurg Anesthesiol.* 2004;16:20-25.
  35. Moore TA, Markert JM, Knowlton RC. Dexmedetomidine as rescue drug during awake craniotomy for cortical motor mapping and tumor resection. *Anesth Analg.* 2006;102:1556-58.
  36. Everett LL, van Rooyen IF, Warner MH, et al. Use of dexmedetomidine in awake craniotomy in adolescents: report of two cases. *Paediatr Anaesth.* 2006;16:338-42.
  37. Ard J, Doyle W, Bekker A. Awake craniotomy with dexmedetomidine in pediatric patients. *J Neurosurg Anesthesiol.* 2003;15:263-266.
  38. Souter MJ, Rozet I, Ojemann JG, et al. Dexmedetomidine sedation during awake craniotomy for seizure resection: effects on electrocorticography. *J Neurosurg Anesthesiol.* 2007;19:38-44.
  39. Kuna ST, Woodson LC, Solanki DR, et al. Effect of progressive mandibular advancement on pharyngeal airway size in anesthetized adults. *Anesthesiology.* 2008;109:605-12.
  40. Tongier WK, Joshi GP, Landers DF, Mickey B. Use of the laryngeal mask airway during awake craniotomy for tumor resection. *J Clin Anesth.* 2000;12:592-94.
  41. Yamamoto F, Kato R, Sato J, Nishino T. Anaesthesia for awake craniotomy with noninvasive positive pressure ventilation. *Br J Anaesth.* 2003;90:382-85.
  42. Huncke T, Chan J, Doyle W, et al. The use of continuous positive airway pressure during an awake craniotomy in a patient with obstructive sleep apnea. *J Clin Anesth.* 2008;20:297-99.
  43. Fukaya C, Katayama Y, Yoshino A, et al. Intraoperative wake-up procedure with propofol and laryngeal mask for optimal excision of brain tumour in eloquent areas. *J Clin Neurosci.* 2001;8:253-55.
  44. Huncke K, Van de WB, Fried I, Rubinstein EH. The asleep-awake-asleep anesthetic technique for intraoperative language mapping. *Neurosurgery.* 1998;42:1312-16.
  45. Olsen KS. The asleep-awake technique using propofol-remifentanyl anaesthesia for awake craniotomy for cerebral tumours. *Eur J Anaesthesiol.* 2008;25:662-69.
  46. Costello TG, Cormack JR, Hoy C, et al. Plasma ropivacaine levels following scalp block for awake craniotomy. *J Neurosurg Anesthesiol.* 2004;16:147-50.
  47. Costello TG, Cormack JR, Mather LE, et al. Plasma levobupivacaine concentrations following scalp block in patients undergoing awake craniotomy. *Br J Anaesth.* 2005;94:848-51.
  48. Costello TG, Cormack JR. Anaesthesia for awake craniotomy: a modern approach. *J Clin Neurosci.* 2004;11:16-19.
  49. Gebhard RE, Berry J, Maggio WW, et al. The successful use of regional anesthesia to prevent involuntary movements in a patient undergoing awake craniotomy. *Anesth Analg.* 2000;91:1230-31.
  50. Archer DP, McKenna JM, Morin L, Ravussin P. Conscious-sedation analgesia during craniotomy for intractable epilepsy: a review of 354 consecutive cases. *Can J Anaesth.* 1988;35:338-44.
  51. Skucas AP, Artru AA. Anesthetic complications of awake craniotomies for epilepsy surgery. *Anesth Analg.* 2006;102:882-87.
  52. Balki M, Manninen PH, McGuire GP, et al. Venous air embolism during awake craniotomy in a supine patient. *Can J Anaesth.* 2003;50:835-38.
  53. Gupta DK, Chandra PS, Ojha BK, et al. Awake craniotomy versus surgery under general anesthesia for resection of intrinsic lesions of eloquent cortex: a prospective randomised study. *Clin Neurol Neurosurg.* 2007;109:335-43.
-

Red Flower Publication Pvt. Ltd.

## CAPTURE YOUR MARKET

*For advertising in this journal*

Please contact:

**International print and online display advertising sales**

*Advertisement Manager*

Phone: 91-11-22756995, 22754205, 45796900, Cell: +91-9821671871

E-mail: sales@rfppl.co.in

**Recruitment and Classified Advertising**

*Advertisement Manager*

Phone: 91-11-22756995, 22754205, 45796900, Cell: +91-9821671871

E-mail: sales@rfppl.co.in

## Evolution of Post Traumatic Acute Thin SDH into Sub acute or Chronic SDH: Analysis of Symptomatology, Risk Factor and Outcomes

R. Selvaraj<sup>1</sup>, A. Agnetia Vinoth<sup>2</sup>

### Abstract

**Introduction:** The natural course of post traumatic acute thin SDH is different among various patients. Most thin SDH resolve spontaneously, a few progress into chronic subdural hematomas requiring surgical treatment. The causative factors for progression of ASDH to CSDH is not fully studied.

**Objectives:** The objectives of this study were to analyse the occurrence of subacute or chronic SDH preceded by the traumatic acute thin SDH and their various presenting symptoms, risk factors, time of presentation, surgical interventions and outcomes.

**Material and methods:** This was a retrospective study conducted at the Institute of Neurosurgery, Madras Medical College. Patients with symptomatic sub acute or chronic SDH following acute post traumatic thin SDH, who were managed conservatively, in the past were included and analysed by database.

**Results:** Totally 20 patients were analysed. All patients underwent burrhole evacuation. Mean age was 47. 75% were alcohol consumers. 10% of patients were on anticoagulants. Presenting symptoms before surgery were headache (70%), dysarthria (20%), hemiparesis (20%), seizure (25%), and drop in GCS (15%). Mean duration between injury and onset of new signs and symptoms was 14 days. Mortality was 10%.

**Conclusion:** Acute thin SDH without surgical treatment liquefies and may later progressively enlarge, so that new symptoms develop in the subacute stage. Furthermore, this pathological process may contribute to the subsequent development of chronic SDH. Mean onset of symptoms was 14 days from our study. Hence, follow up imaging at end of 2<sup>nd</sup> week is advisable to identify the enlarging SDH which leads to help in early surgical intervention and prevent irreversible brain damage.

**Keywords:** Acute Subdural hematoma; Chronic subdural hematoma.

### How to cite this article:

R. Selvaraj, A. Agnetia Vinoth. Evolution of Post Traumatic Acute Thin SDH into Sub acute or Chronic SDH: Analysis of Symptomatology, Risk Factor and Outcomes. Int J Neurol Neurosurg. 2019;11(2):131-136.

### Introduction

Post-traumatic subdural fluid collections have been known to contribute to the development of

chronic SDH [1]. Although there have been a few reports documenting the occurrence of chronic SDH originating from acute SDH, the relationship between acute SDH and chronic SDH is not fully studied [1]. The natural course of post traumatic acute thin SDH is different among patients. Although most resolve spontaneously, few do not disappear and instead progress to chronic subdural hematoma (CSDH) requiring surgical treatment. Progression of ASDH to CSDH is a common cause of clinical deterioration in patients with initially non-operated ASDH. To understand this relationship, we analysed adult patients with symptomatic Sub acute or chronic SDH who initially had an acute thin SDH that was managed conservatively in the past.

**Author's Affiliation:** <sup>1</sup>Associate Professor <sup>2</sup>Resident, Dept. of Neurosurgery, Institute of Neurosurgery, Rajiv Gandhi Govt General Hospital, Madras Medical College, Chennai, Tamil Nadu 600003, India.

**Corresponding Author:** A. Agnetia Vinoth, Resident, Dept. of Neurosurgery, Institute of Neurosurgery, Rajiv Gandhi Govt General Hospital, Madras Medical College, Chennai, Tamil Nadu 600003, India.

**E-mail:** [dr\\_agnetia@yahoo.co.in](mailto:dr_agnetia@yahoo.co.in)

**Received on** 09.02.2019, **Accepted on** 06.03.2019

### Aims

To study the occurrence of subacute and chronic SDH following a traumatic acute thin SDH. Additionally the various presenting symptoms, risk factors, time of presentation, surgical interventions performed and their outcomes were analysed.

### Material and methods

This study was a retrospective observational study conducted at the Institute of Neurosurgery, Madras Medical College. 20 consecutive patients with symptomatic sub-acute or chronic SDH following an acute post traumatic thin SDH who were managed conservatively in the past were included. Patient's details and imaging were collected from medical records between January 2018 to June 2018.

#### Clinical data

Retrospectively various symptoms such as head ache, seizure, limb weakness, altered sensorium and various risk factors such as age, alcoholism, anticoagulant utilisation etc were analysed. The time of presentation surgical management and outcome were also analysed. Patients with associated contusions and haemorrhage causing mass effect were excluded and subdural hygroma patients were also excluded.

#### Statistical analysis

The data was entered as spread sheets and analysed using Microsoft Excel 2010. Descriptive statistics were calculated as frequency, percentage, mean and standard deviation. The data were represented as various tables and also in the form of graphs such as bar charts and pie diagrams.

### Results

20 patients were analysed of which 16 patients were males and 4 females. The hematoma was predominantly in the front-parietal region and predominantly in the right side and all patients underwent frontal and parietal burrholes and evacuation of the SDH. The mean age was 47. 75% of the patients were alcohol consumer. 10% of the patients were on anticoagulants. All patients had mild head injuries at the time of admission (GCS > 12). Presenting symptoms before surgery were headache (70%), dysarthria (20%), hemiparesis (20%), seizure (25%), and drop in GCS

(15%). On analysis of Pre-op GCS, 80% of patients presented between 13-15, 10% patients between 9-12 and 10% were between 3-8. Mean duration between injury and onset of new signs and symptoms was 14 days. Mortality was 10%.

**Table 1:** Age distribution of the study subjects (n=20)

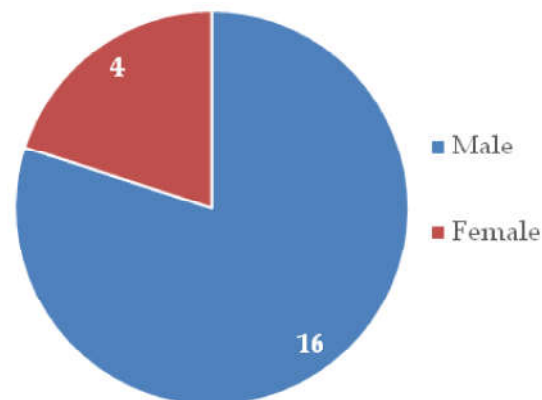
Age group	Frequency	Percent
30 to 40 years	4	20.0
41 to 50 years	9	45.0
51 to 60 years	4	20.0
61 to 70 years	0	0
71 to 80 years	3	15
Total	20	100

Mean ( $\pm$  S.D) = 49.3 ( $\pm$  11.51) years

Minimum Age: 30 years      Maximum Age: 72 years

**Table 2:** Gender distribution of the study subjects (n=20)

Gender	Frequency	Percent
Male	16	80.0
Female	4	20.0
Total	20	100



**Fig. 1:** Pie chart showing Gender distribution of the study subjects (n=20)

**Table 3:** Mode of Injury of the study subjects (n=20)

Mode of Injury	Frequency	Percent
Road traffic accident	16	80.0
Fall from Height	2	10.0
SF	2	10.0
Total	20	100

**Table 4:** Distribution of Risk factors in the study subjects (n=20)

Risk factors	Frequency	Percent
Alcoholism	14	70.0
Anticoagulant medication	2	10.0
Diabetes Mellitus	3	15.0
Hypertension	5	25.0
Coronary artery disease	2	10.0

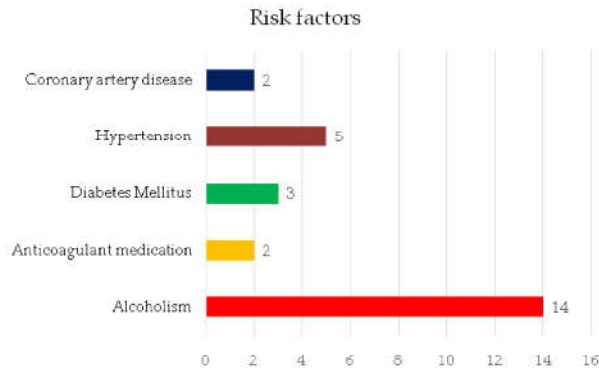


Fig. 2: Distribution of Risk factors in the study subjects (n=20)

Table 5: Distribution of presenting symptoms (n=20)

Symptoms*	Frequency	Percent
Headache	14	70.0
Hemiparesis	4	20.0
Seizure	4	20.0
Dysarthria	2	10.0
Drop in GCS	4	20.0

\*Not mutually exclusive

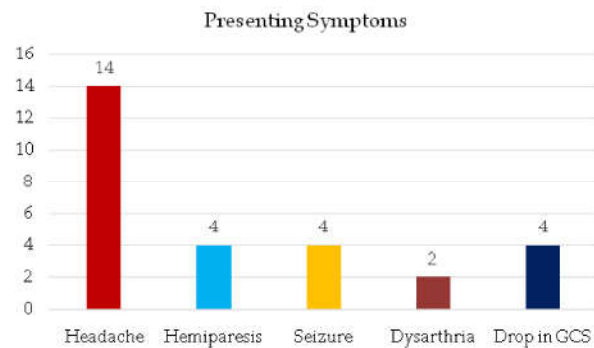


Fig. 3: Bar chart showing presenting symptoms

Table 6: Distribution according to diagnosis (n=20)

Diagnosis	Frequency	Percent
Fronto-parietal chronic SDH	10	50.0
Fronto-temporo-parietal chronic SDH	10	50.0

Side of chronic SDH	Frequency	Percent
Left side	14	70.0
Right side	6	30.0

Table 7: Distribution of GCS at injury (n=20)

Diagnosis	Frequency	Percent
12	2	10.0
14	4	20.0
15	14	70.0

Table 8: Distribution of pre-operative GCS (n=20)

Diagnosis	Frequency	Percent
13 to 15	16	80
9 to 12	2	10.0
3 to 8	2	10.0

Table 9: Distribution of time between injury and onset of symptoms (n=20)

Mean ( $\pm$  S.D) = 14.9 ( $\pm$  4.49) days  
 Minimum: 10 days                      Maximum: 28 days

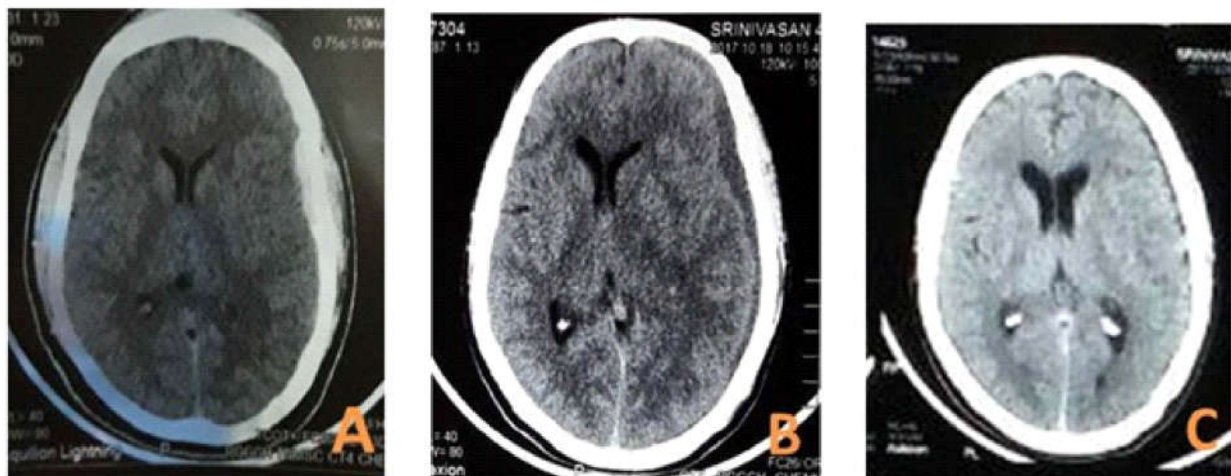


Fig. 4: Case 1. CT scans of 45 year old male with history of RTA. A: on admission. B: on day 14. C: post burrhole evacuation.

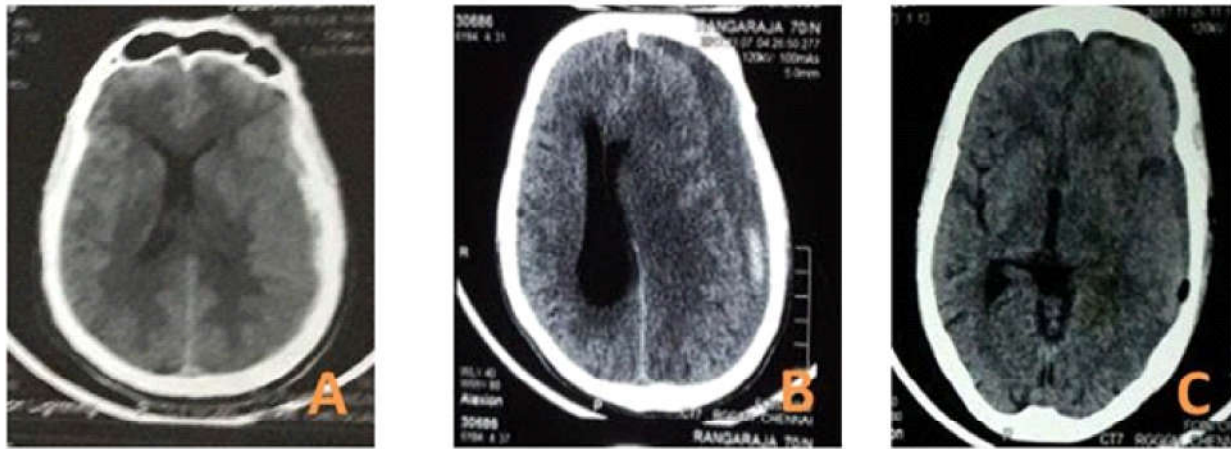


Fig. 5: Case 2. CT scans of 70 year old male with history of RTA. A: on admission. B: on day 15. C: post burrhole evacuation.

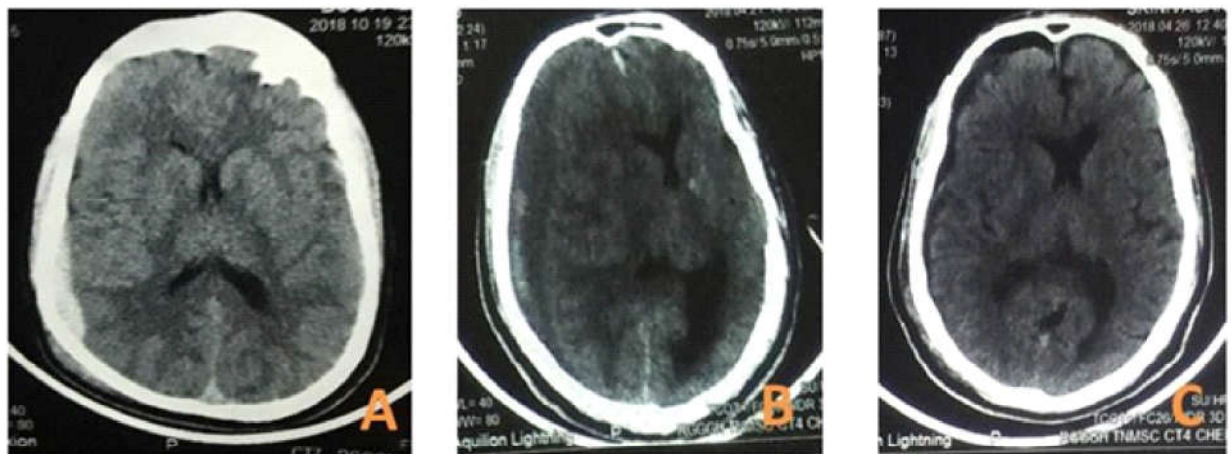


Fig. 6: Case 3. CT scans of 54 year old female with history of RTA. A: on admission. B: on day 17. C: post burrhole evacuation.

## Discussion

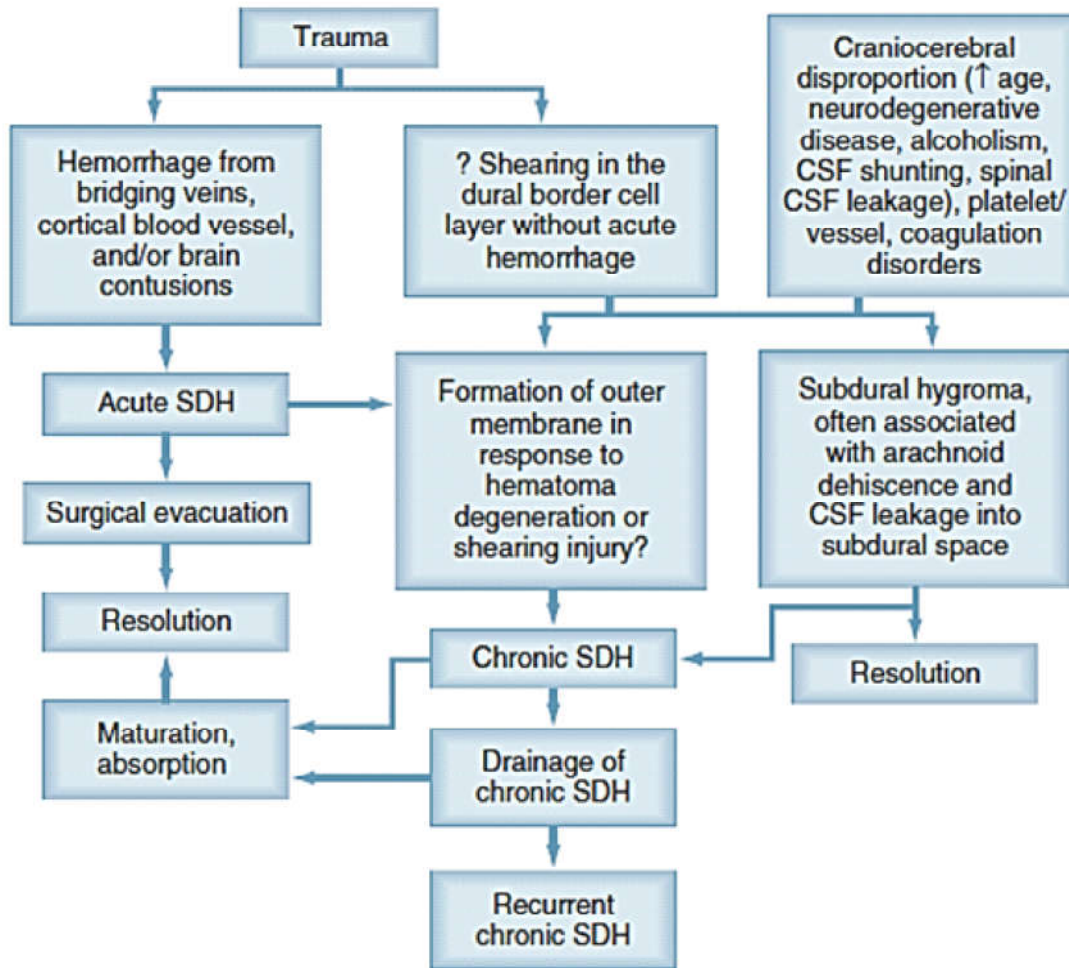
Generally, hematoma with a thickness greater than 10 mm, or a midline shift greater than 5 mm are suggested as critical indicators for surgical removal of ASDH regardless of the Glasgow Coma Scale scores [2]. However, when these criteria are not met, ASDH does not require surgical treatment as it can resolve spontaneously. Conservative management is possible, if the patient shows mild neurologic deficit or brain CT does not show any mass effect [3]. However, of these cases, some of them aggravate to form ASDH in the chronic healing stage or progress to CSDH, requiring surgical intervention [4].

Until now, only a handful of studies have specifically addressed the issue of the rate of CSDH progression after conservative treatment of trauma-related ASDH. Generally, 3% to 26% of patients with ASDH, who were managed conservatively, developed chronic SDHs requiring evacuation [5,6].

CSDH can evolve from acute SDH or subdural effusion. However, only a few reports document the occurrence of chronic SDH in patients with acute SDH. Sub acute and chronic subdural haematomas are a common problem in the elderly population. Its pathogenesis has been discussed in the literature for decades. The issues remaining to be solved with regard to CSDH include the initiating events (the bleeding into the subdural space and the formation of the outer and inner membranes), its development (increase and liquefaction of hematoma), the optimal treatments, and the natural history of the disease.

In the present series, in 90% of the patients, the SDH resolved after subdural tapping in the subacute stage when new symptoms developed; however, if they were not treated at the time, the transformation into chronic SDH could ensue.

Radiologically 75% of the patients had mixed density in the initial CT scans this was, therefore, found to be a significant factor for development



**Flow chart 1:** clinical factors that contribute to formation of a chronic subdural hematoma. CSF, cerebrospinal fluid; SDH, subdural hematoma

of subacute or chronic SDH. Mixed hematoma density could also be due to cerebrospinal fluid (CSF) mixed with the hematoma. In this situation, the arachnoid membrane is frequently torn, which causes a mixture of CSF and blood to accumulate in the subdural space. Head CT scans usually reveal an expansive lesion with a low density area in the hematoma. This CSF mixture may exhibit rapid resolution within 24 hours due to dilution of the hematoma by CSF. On the other hand, steady CSF leakage from the subarachnoid space can cause worsening due to CSF accumulation during the subacute phase [8,9].

Seong Son, M.D., et al., postulated in their article in 2013 two possible mechanisms for subacute worsening 1) delayed resolution of hematoma in conditions such as acute-on-chronic SDH or thick ASDH, 2) subacute CSF accumulation in the subdural space in conditions such as CSF mixed ASDH or brain atrophy [7].

Alcoholism and anticoagulants are major risk

factors in developing symptomatic sub acute SDH and the most common symptom is a progressive severe headache. Mortality is 10% in this series, with mortality being more associated with prior anticoagulant intake.

The factors for spontaneous resolution include no anticoagulant medication, homogeneous density, mild midline shift, thin hematoma, fewer CT slices containing hematoma, and the absence of brain atrophy [7].

#### Limitations

This study has several limitations that warrant consideration. Foremost, its retrospective nature is intrinsically prone to patient-selection bias. In addition, we only examined symptomatic sub acute or chronic SDH who were found to have a history of post traumatic acute thin SDH managed conservatively in the past however asymptomatic and spontaneously resolved patients were not

included in the study the hence exact incident of progression and factors favouring spontaneous resolution could not be derived. The sample size was also too small to analyse further risk factors. Finally this was a single institution study.

#### *Future directions*

We need prospective studies which include all post traumatic acute thin SDH and should also include larger number of samples to validate the risk factors. Future studies may include all radiological characters and special investigations.

#### **Conclusion**

Acute thin SDH without surgical treatment undergo liquefaction and may progressively enlarge, so that new symptoms develop in the subacute stage. Furthermore, this pathological process may contribute to the subsequent development of chronic SDH. Mean onset of symptoms is 14 days from our study. Hence follow up imaging at end of 2<sup>nd</sup> week is advisable to identify the enlarging SDH which leads to early surgical intervention and prevents irreversible brain damage. Clearly, no single parameter accurately predicts ASDH progression, but patients with risk factors should be monitored carefully for progression.

*Financial conflicts of interest:* None

#### **References**

1. Yoshitaro Yamaguchi, Tatsuo Hayashi, and Hiroaki Sekino. Evolution from Acute Subdural Hematomas to Chronic Subdural Hematomas. Division of Neurosurgery, Second Department of Surgery, St. Marianna University School of Medicine, Kawasaki, Kanagawa, 216 Japan.
2. Bullock MR, Chesnut R, Ghajar J, Gordon D, Hartl R, Newell DW, et al. Surgical management of acute subdural hematomas. *Neurosurgery*. 2006;58 (3 Suppl):S16-S24.
3. Feliciano CE, De Jesús O. Conservative management outcomes of traumatic acute subdural hematomas. *P R Health Sci J*. 2008;27:220-23.
4. Yamashita T, Yamamoto S. Clinicopathological study of acute subdural haematoma in the chronic healing stage. Clinical, histological and ultrastructural comparisons with chronic subdural haematoma. *Neurochirurgia (Stuttg)*. 1984;27:98-105.
5. Lindvall P, Koskinen LO. Anticoagulants and antiplatelet agents and the risk of development and recurrence of chronic subdural haematomas. *J Clin Neurosci*. 2009;16:1287-90.
6. Mathew P, Oluoch-Olunya DL, Condon BR, Bullock R. Acute subdural haematoma in the conscious patient: outcome with initial non-operative management. *Acta Neurochir (Wien)*. 1993;121:100-108.
7. Seong Son, Chan Jong Yoo, Sang Gu Lee, et al., Natural Course of Initially Non-Operated Cases of Acute Subdural Hematoma: The Risk Factors of Hematoma Progression. *J Korean Neurosurg Soc*. 2013 Sep;54(3):211-19.
8. Kim H, Shim YB, Chung DJ, Kim SM, Park YK, Choi SK. Rapid spontaneous resolution of acute subdural hematoma. *J Korean Neurosurg Soc*. 1999;28:1636-38.
9. Lee CH, Kang DH, Hwang SH, Park IS, Jung JM, Han JW. Spontaneous rapid reduction of a large acute subdural hematoma. *J Korean Med Sci*. 2009;24:1224-26.



## Diffuse Axonal Injury: An institute Experience

Swarnarekha Narayanan<sup>1</sup>, Sai Sriram S.<sup>2</sup>, Balasubramanian D.<sup>3</sup>

### Abstract

**Introduction:** Traumatic Brain Injuries are among the leading cause of mortality and morbidity world over. They are the leading cause of death among the younger age groups accounting for several indirect social and economic problems. This becomes more important in developing nations like India.

**Methodology:** 30 pediatric and 30 adult patients that were admitted and diagnosed to have Diffuse axonal Injury were included in our study. The duration of the study was 6 months between June and November 2018 in the Institute of Neurosurgery, Madras Medical College.

**Discussion:** Diffuse axonal injury is caused from widespread tearing of axons and small vessels by shearing forces and is defined as prolonged post-traumatic coma over 6 hours following injury without demonstrable mass lesion.

**Results:** Of the 21 patients with Grade 1 DAI, all 21 had favorable outcome as defined by GOS 4 or 5. 13 of the 20 in Grade 2 DAI had favourable outcomes while only 5 of the 19 with Grade 3 DAI had favourable outcomes.

**Conclusion:** In our study we were able to find out that while there was a statistically significant correlation between grade of DAI and the outcome ( $p=0.002$ ), there was no statistically significant correlation between gender and the outcomes ( $p=0.3$ ).

**Keywords:** Diffuse Axonal Injury; Traumatic Brain Injury; Mortality; Pediatrics.

### How to cite this article:

Swarnarekha Narayanan, Sai Sriram S., Balasubramanian D. Diffuse Axonal Injury: An institute Experience. Int J Neurol Neurosurg. 2019;11(2):137-140.

### Introduction

Traumatic Brain Injuries are among the leading cause of mortality and morbidity world over. They are the leading cause of death among the younger

age groups accounting for several indirect social and economic problems. This becomes more important in developing nations like India. As per report by the ministry of road transport, Government of India (2007) 1.4 lakhs road accident happened in 2007 with 40,612 people killed and 1.5 lakhs people injured [1,2]. Hence, India is leading the world in fatalities due to road accidents. With the increasing use of MRI, Diffuse Axonal Injury is reported far more frequently. While recovery from DAI is dependent on the grade of the Injury, in our study we attempt to establish a correlation between age and outcomes.

TBI in children often occur in the same manner as in adults but differ in both pathophysiology and management. The differences are attributable to age-related structural change, mechanism of injuries based on physical ability of the child, and

**Author's Affiliation:** <sup>1</sup>Assistant Professor, <sup>2</sup>Post Graduate Resident, <sup>3</sup>Professor, Dept. of Neurosurgery, Institute of Neurosurgery, Madras Medical College, Chennai, Tamil Nadu 600003, India.

**Corresponding Author:** Sai Sriram S., Post Graduate Resident, Dept. of Neurosurgery, Institute of Neurosurgery, Madras Medical College, Chennai, Tamil Nadu 600003, India.

**E-mail:** [saisriram1989@gmail.com](mailto:saisriram1989@gmail.com)

**Received on 29.03.2019, Accepted on 04.05.2019**

the difficulty in neurological evaluation of pediatric populations [3]. Several small case series of DAI in children, using differing imaging methods, found varying outcomes and were unable to correlate injury with prognosis [4,5,6,7]. Advances in diagnostic imaging have improved the quality of care by assisting healthcare providers to evaluate and diagnose children with TBI.

### Materials and Methods

Thirty (30) pediatric and 30 adult patients that were admitted and diagnosed to have Diffuse axonal Injury were included in our study. The duration of the study was 6 months between June and November 2018 in the Institute of Neurosurgery, Madras Medical College. Patients were assessed based on their admitting GCS, associated injuries, duration of coma and these were correlated with outcome at the time of discharge as defined by Glasgow Outcome Score as favourable (GOS-4 and 5) or unfavourable (GOS 1,2 and 3). Patients with hypotension and significant injury to other systems which required intervention were excluded from the study. DAI was defined based on the description by Gennarelli et al. An MRI finding of scattered small hemorrhagic lesions on hemispheric white matter was classified as grade I, a finding of additional focal lesions on the corpus callosum was classified as grade II, and a finding of additional focal lesions on the brain stem was classified as grade III. The correlation between the MRI grade and the mean time interval to recovery of consciousness was evaluated by one-way analysis of variance (ANOVA). Statistical significance was defined as  $p < 0.05$ .

### Results

Of the 60 patients in the study, 43 were men and 17 were women.

Among the pediatric patients, 12 had Grade 1 DAI, 11 had Grade 2 DAI and the remaining 7 had Grade 3 DAI. Among the adults, 9 patients had Grade 1 DAI, 9 more had Grade 2 DAI and 12 had Grade 3 DAI.

The gender distribution among the pediatric patients was 8 boys and 4 girls had Grade 1 DAI, 7 boys and 4 girls had Grade 2 DAI while 4 boys and 3 girls had DAI of Grade 3. Among the adults, 8 men and a woman had Grade 1 DAI. Grade 2 DAI was noted in 7 men and 2 women while 10 men and 2 women had grade 3 DAI.

Of the 21 patients with Grade 1 DAI, all 21 had favorable outcome as defined by GOS 4 or 5. 13 of the 20 in Grade 2 DAI had favourable outcomes while only 5 of the 19 with Grade 3 DAI had favourable outcomes. There was a statistically significant correlation with  $p$  value of 0.002.

23 of the 30 pediatric patients had a favourable outcome. It included all 12 who had Grade 1 DAI, 8 of the 11 with Grade 2 DAI and 3 of the 7 with Grade 3 DAI.

Among the adults, 16 of the 30 had favorable outcomes. 9 belonged to Grade 1 DAI, 5 had Grade 2 DAI while only 2 of the 12 with Grade 3 DAI had favourable outcomes.

There was a statistically significant correlation between age and outcome with a  $p$  value of 0.03.

### Discussion

Diffuse axonal injury is caused from widespread tearing of axons and small vessels by shearing forces and is defined as prolonged post-traumatic coma over 6 hours following injury without demonstrable mass lesion [8,9,10]. "Diffuse degeneration of the cerebral white matter" was first defined by Strich [11]. The time course of the pathological changes was established by Adams et al. [12]. Studies have suggested that children with deeper lesions are more likely to have poor outcomes, the so-called Ommaya-Gennarelli hypothesis [13,14,15].

The Ommaya-Gennarelli depth of lesion model was used to create the Adams classification for animal studies. Mild (grade 1) DAI includes microscopic changes in subcortical white matter, corpus callosum, brainstem, and cerebellum. Moderate (grade 2) DAI is defined by grossly evident focal lesions isolated to the corpus callosum. Severe DAI (grade 3) includes additional focal lesions in the dorsolateral rostral brainstem [16]. Although useful for animal studies, it is uncertain how well this classification translates to the clinical setting. In one study, patients with DAI lesions limited to subcortical white matter had better outcomes than patients with injury to the corpus callosum or brainstem [17]. Other investigators found a high incidence of brainstem hemorrhage in patients with more severe TBI and DAI.

There are unique biomechanical properties for pediatric brain injury due to a combination of higher plasticity and deformity, whereby external forces are absorbed in a different way compared to adults. The infant skull is less rigid, and open

sutures function as joints, allowing for a small degree of movement in response to a mechanical stress. The cerebral white matter contains little myelin, and its distribution is very different in newborns compared with that in adults. The neonatal brain is watery, while the myelinated brain has a much higher density due to the progressing myelination and progressively lowering of the water content. Temporal differences between myelination of various brain areas are pronounced during progressing development. Myelination follows programmed patterns with a caudo-cranial and posterior-anterior predominance. The degree of myelination results in different absorption of traumatic forces, with increased susceptibility to TBI in the unmyelinated regions [19].

Diffuse axonal injury can be diagnosed using clinical signs (level of consciousness and neurological deficits) and radiological findings. Zimmerman reported the first study of radiological diagnosis of diffuse axonal injury that includes small hemorrhagic lesions on the corpus callosum, upper brain stem, corticomedullary junction, parasagittal area, and basal ganglia. Brain computed tomographic (CT) findings lack accuracy in the prediction of a patient's outcome and do not correspond well to the patient's GCS score or neurological state [20].

### Conclusion

In our study we were able to find out that while there was a statistically significant correlation between grade of DAI and the outcome ( $p=0.002$ ), there was no statistically significant correlation between gender and the outcomes ( $p=0.3$ ). However, we were able to establish a statistically significant correlation between age of the patient and the outcome ( $p=0.03$ ). A greater percentage of pediatric patients had a better outcome compared to their adult counterparts. These findings of our study are in line with several studies that have concluded that pediatric populations tend to show comparatively better recovery than the adult populace.

Given the increasing incidence of DAI and the increasing number of pediatric patients being affected, further studies are needed to better prognosticate this condition which may have long lasting impact on the growing child and the plastic brain and ipso facto, be a significant factor in the development of the child and by extension, the community.

### References

1. Samabasivan M. Epidemiology of Neurotrauma. Neurology and Prevention. *Neurol India (Supl)* 1991;43:915.
2. Ramamurthi B. Road accidents, Epidemiology and Prevention. *Neurol India (Supl)*. 1991;43:915.
3. Ghajar J, Hariri RJ: Management of pediatric head injury. *PediatrClin North Am*. 1992;39:1093-1125.
4. Chiaretti A, Visocchi M, Viola L, et al. Diffuse axonal lesions in childhood. *Pediatr Med Chir*. 1998;20:393-397.
5. Vowles GH, Scholtz CL, Cameron JM. Diffuse axonal injury in early infancy. *J Clin Pathol*. 1987;40:185-89.
6. Kurihara M, Kumagai K, Nakae Y. Functional outcome after diffuse axonal injury in childhood traumatic brain injury. *No To Hattatsu*. 1999;31:408-14.
7. Gleckman AM, Bell MD, Evans RJ, Smith TW. Diffuse axonal injury in infants with nonaccidental craniocerebral trauma: enhanced detection by beta-amyloid precursor protein immunohistochemical staining. *Arch Pathol Lab Med*. 1999;123:146-51.
8. Alberico AM, Ward JD, Choi SC, Marmarou A, Young HF. Outcome after severe head injury : relationship to mass lesions, diffuse injury, and ICP course in pediatric and adult patients. *J Neurosurg*. 1987;67:648-56.
9. Eisenberg HM, Gary HE, Jr, Aldrich EF, Saydjari C, Turner B, Foulkes MA, et al. Initial CT findings in 753 patients with severe head injury. A report from the NIH Traumatic Coma Data Bank. *J Neurosurg*. 1990;73:688-98.
10. Eum SW, Lim DJ, Kim BR, Cho TH, Park JY, Suh JK, et al. Prognostic factors in patients with diffuse axonal injury. *J Korean Neurosurg Soc*. 1998;27:1668-74.
11. Strich SJ. Diffuse degeneration of the cerebral white matter in severe dementia following head injury. *J NeurolNeurosurg Psychiatry*. 1956;19:163-85.
12. Adams H, Mitchell DE, Graham DI, Doyle D. Diffuse brain damage of immediate impact type. Its relationship to "primary brain stem damage" in head injury. *Brain*. 1977;100:489-502.
13. Cordobes F, Lobato RD, Rivas JJ, et al. Post-traumatic diffuse axonal brain injury. Analysis of 78 patients studied with computed tomography. *ActaNeurochir (Wien)*. 1986;81:27-35.
14. Ommaya AK, Gennarelli TA. Cerebral concussion and traumatic unconsciousness. Correlation of experimental and clinical observations of blunt head injuries. *Brain* 1974;97:633-54.
15. Grados MA, Slomine BS, Gerring JP, et al. Depth of lesion model in children and adolescents with moderate to severe traumatic brain injury: use

- of SPGR MRI to predict severity and outcome. *J NeurolNeurosurg Psychiatry*. 2001;70:350-58.
16. Gentry LR. Imaging of closed head injury. *Radiology* 1994;191:1-17.
  17. Kampfl A, Schmutzhard E, Franz G, et al. Prediction of recovery from post-traumatic vegetative state with cerebral magnetic resonance imaging. *Lancet*. 1998;351:1763-67.
  18. Cordobes F, Lobato RD, Rivas JJ, et al. Post-traumatic diffuse axonal brain injury. Analysis of 78 patients studied with computed tomography. *Acta Neurochir (Wien)*. 1986;81:27-35.
  19. Stark MJ, Hodyl NA, Belegar V KK, Andersen CC. Intrauterine inflammation, cerebral oxygen consumption and susceptibility to early brain injury in very preterm newborns. *Arch Dis Child Fetal Neonatal Ed*. 2016;101:F137- F142.
  20. Duhaime AC, Christian CW, Rorke LB, Zimmerman RA. Nonaccidental head injury in infants—the “shaken-baby syndrome.” *N Engl J Med*. 1998;338:1822-29.
-

## Clinical Profile of Unknown Patients with Head Injuries in a Tertiary Care Centre in India: Clinical Profile and Outcome

Swarnarekha Narayanan<sup>1</sup>, Krishna Narayanan M.D.<sup>2</sup>, Balasubramanian D.<sup>3</sup>

### Abstract

**Background:** Unknown patients represent a particularly vulnerable group. They are usually neglected individuals, with improper access to proper nutrition, sanitation and health care. They often harbour numerous comorbidities that are undiagnosed and untreated at the time of presentation and the management of such patients is particularly difficult.

**Objective:** To analyze the clinical profile and outcome of patients admitted as 'Unknown' with Head injuries.

**Setting:** Institute of neurosurgery, Madras Medical College.

**Subjects:** Patient data was obtained by retrospectively from hospital records, records were perused from January 2014 to January 2019. Data was collected regarding patients admitted as 'Unknown' with Head Injuries.

**Results:** A total of 110 patients were enrolled into the study. 28 patients were found to have severe head injuries, 60 patients were found to have moderate injuries and 22 patients were found to have mild head injuries. 14 patients succumbed, 5 patients were successfully rehabilitated with their families and are on long term follow up, 61 patients were discharged to rehabilitation homes and lost to follow up. 30 patients left the hospital of their own volition.

**Conclusion:** Unknown patients are an often marginalised, under represented and vulnerable subset of the Head Injury population. By describing the magnitude of the problem and the peculiar difficulties seen in treating these patients, we hope, to bring these individuals to the foreground and restate that they require a particularly empathetic approach.

**Keywords:** Unknown; Traumatic brain injury; Outcome.

### How to cite this article:

Swarnarekha Narayanan, Krishna Narayanan M.D., Balasubramanian D. Clinical Profile of Unknown Patients with Head Injuries in a Tertiary Care Centre in India: Clinical Profile and Outcome. Int J Neurol Neurosurg. 2019;11(2):141-144.

### Introduction

Head injuries represent a devastating, preventable disease entity that has shown a consistent and considerable rise in Incidence

over the years, especially in developing countries where the rate of growth in consumer wealth and number of vehicles has far outstripped the infrastructural investment in safety. While the exact Incidence in India is unknown, most studies in India rely on extrapolation of data available from developed countries [1]. The obvious limitation of this being the higher population density in India and the difference in local legislation. What is known is that the incidence of Head injuries is on the rise.

Unknown patients represent a particularly vulnerable group. They are usually neglected individuals, with improper access to proper nutrition, sanitation and health care. They often harbour numerous comorbidities that are undiagnosed and untreated at the time of presentation and the management of such patients

**Author's Affiliation:** <sup>1</sup>Assistant Professor, <sup>2</sup>Resident, <sup>3</sup>Professor, Dept. of Neurosurgery, Rajiv Gandhi Government General Hospital and Madras Medical College, Park town, Chennai, Tamil Nadu, India 600003, India.

**Corresponding Author:** Krishna Narayanan M.D., Resident, Dept. of Neurosurgery, Rajiv Gandhi Government General Hospital and Madras Medical College, Park town, Chennai, Tamil Nadu, India 600003, India.

**E-mail:** [mdknarayanan@gmail.com](mailto:mdknarayanan@gmail.com)

**Received on** 18.04.2019, **Accepted on** 10.05.2019

is particularly difficult. Studies on the outcome of head injuries in such patients are sparse [2]. Further information on such patients would better help the physician to treat such patients and furthermore guide legislation and policy changes to ensure that such patients do not 'fall off the grid'.

## Materials and Methods

The study was conducted at the Institute of neurosurgery, Madras Medical College after obtaining clearance from the institutional ethics committee.

Patient data was obtained retrospectively from hospital records, records were perused from January 2014 to January 2019.

The Aim was to analyze the clinical profile and outcome of patients admitted as 'Unknown' with Head injuries.

### *Participants and procedure*

Upon retrospective analysis, a total of 110 patients were identified. Records of these patients was perused and data was analysed based on patient demographics, Injury characteristics and ultimate outcome.

Patients who survived were further classified based on their mode of rehabilitation i.e. patients that were successfully identified and reconnected with their support network (family or otherwise), patients discharged to Rehabilitation centers/ temporary homes and patients who left of their own free will against medical advice. The data of their outcome was further studied against available literature to ascertain if there was a significant difference in outcome after further stratifying patients based on the severity of their head injury.

### *Inclusion criteria*

Patients with mild, moderate or severe head injuries with or without other injuries with no obvious identification at the time of admission and 24 hours post admission after an initial exhaustive search for next of kin.

### *Exclusion criteria*

Patients who were identified and were reunited with their families within 24 hours of Injury and patients who were declared dead on arrival or died prior to resuscitation and evaluation for injuries.

## *Statistical Analysis*

Apart from descriptive statistics, all other statistical analyses were carried out using the IBM SPSS software for Windows.

## Results

A total of 110 patients were enrolled into the study, with the vast majority of patients being male (100 of 110/ 90.9%). This is as most traumatic Injuries in India affect men and that most patients with no next of kin or 'Unknown' patients are male.

The youngest patient in the study was 14 years old (approximated using limb x-rays) and the oldest patient was approximated to be around 80 years of age. The age wise distribution of patients is tabulated in Table 1.

Head injuries were classified and quantified as mild moderate and severe using the following criteria (based on the Glasgow Coma Scale/ GCS): severe (GCS<8), moderate (GCS 9-13), and minor (GCS 14-15) [3]. Using this classification, 28 patients were found to have severe head injuries, 60 patients were found to have moderate injuries and 22 patients were found to have mild head injuries. This is tabulated in Table 2.

Upon admission and treatment, 14 patients succumbed, of which 13 patients had a severe head injury at the time of admission and 1 patient had a moderate head injury but later succumbed to an underlying undiagnosed cardiomyopathy, 26 hours after admission. Of the remaining patients, 5 patients were successfully rehabilitated with their families and are on long term follow up, 61 patients were discharged to rehabilitation homes and lost to follow up. 30 patients (20 with mild head injuries and 10 with moderate) left the hospital of their own volition, against medical advice and were also lost to follow up, Table 3.

**Table 1:** Age wise distribution of 'Unknown patients' with Head Injuries

Age Distribution (in years)	Number of Patients
1-10	0
11-20	4
21-30	28
31-40	30
41-50	18
51-60	18
61-70	9
71-80	3
Above 80	0

**Table 2:** Tabulation of patients vs presenting GCS

Presenting GCS	Number of Patients
GCS < 8	28
GCS 9-13	60
GCS 14-15	22

**Table 3:** Patient Outcome

Outcome	Number of Patients
Expired	14
Identified, discharged to family	5
Discharged to Rehabilitation home	61
Left against medical advice	30

**Table 4:** Characteristics of sustained Head Injuries

Type of Injury	Number of Patients
Epidural Hematoma	14
Subdural Hematoma	36
Contusion / Intracerebral Hematoma	17
Calvarial Fracture	7
Pneumocephalus	6
Pneumoventricle or Intraventricular Hematoma	4
Diffuse Axonal Injury	19
Mixed Lesions	7

The characteristics of the head injuries of the patients are tabulated in Table 4.

## Discussion

The category of patients listed as 'Unknown' represent an uniquely vulnerable subset of patients. These patients pose numerous challenges both in terms of their treatment parameters as well as to the treating institute. The problem is further confounded by the relative paucity of reliable data, owing to the inconsistent terminology used in literature. The burden of care for these patients rests exclusively on the treating physician and the supporting hospital. As these patients invariably are treated in government run institutions they tend to stress hospital resources in a background of already limited supplies [4].

Head injuries in these patients further compound the problem, as at the time of presentation, most of these patients are obtunded and any history of comorbid illnesses (if known) cannot be elicited and the baseline cognitive performance is unknown. This potentially leads to a dilemma and delay in treatment as the rapid neurologic exam performed in the emergency department is primarily based on the implication that the patient

had no psychomotor symptomatology prior to the inciting trauma [5]. Moreover resuscitation of these patients are also a challenge as their underlying cardio pulmonary status is unknown leading to an approximation of medication and underlying metabolic derangements are only diagnosed after a few hours, when investigations are available. This was exemplified by the loss of one patient in this study with a moderate head injury with an unreported/undiagnosed cardiomyopathy who went into cardiac failure following the initial resuscitation and subsequently succumbed.

This study revealed that a disproportionately large portion of the 'Unknown' patients were male. The reason behind this is largely unknown as no available indices for such patients exist in India and therefore it cannot be ascertained if this represents a sampling bias or is reflective of the state of events. However it was noted that most of the female patients were above the age of 60 (8 of 10 / 80%). Additionally, of the patients who were successfully reunited with their families (5 of 110), all were less than 30 years of age. It was found that the older the patient, the more difficult it was to find their place of origin and surviving family members (if any).

The pattern of injuries were consistent with high velocity impact trauma [6] and the common mode of presentation was secondary to a road traffic accident, wherein the patient was almost always the pedestrian, this likely was due to encroachment of these individuals onto roads, inebriation of the driver, inebriation of the patient or both. The mortality indices were also consistent with available literature [7], the difference being a statistically non significant decrease in patients dying of severe head injuries (global average 46 % vs 45%) [8], the possible reasons include an longer than average ICU stay, a longer than average in patient course and the fact that the primary care giver was usually a trained para medical professional.

Of the patients admitted and successfully treated, only 5 patients were successfully reunited with their family. The large majority of patients either left the hospital of their own accord or were discharged to long term care facilities. The troubling aspect of this was that these patients were subsequently lost to follow up, indicating that while they were successfully treated for their injuries, their long term rehabilitation was most likely incomplete. It is a known fact that head injuries leave lasting psychomotor and cognitive disabilities [9,10,11], that require long term treatment and follow up. The absence of such treatment likely sets up a vicious cycle, wherein the successful reintegration of the

patient to society is hampered by the additional disabilities sustained during the trauma.

The only large scale study conducted in India to date [2] cites the logistical and medical issues that are highlighted in this paper, in comparison we found a larger subset of patients that remained unidentified. The possible reasons include, the larger intake of this hospital, the larger treating radius and referral radius as well as the general growth of the Indian population since the publication of the afore mentioned article.

The paucity of data on these patients, further indicates the marginalisation of such individuals. While most hospitals do receive such patients, they are often ill equipped to deal with a problem of such a magnitude. This study emphasises the fact that a systemic redressal of the problem should be sought for at every level. Rather than considering such individuals as patients alone, the hospital should be considered as the point of first contact, wherein rehabilitation and repatriation into society can begin as the patient is being treated.

Moreover, prompt identification of such patients would be beneficial to both the treating physician and the patient, this again requires an uniform medical record system and an identification system. however the sheer magnitude of such an endeavour in a country as populous as India is probably arduous, both in terms of data acquisition and in a medicolegal stand point, especially at a time where data breaches and concerns over privacy are the norm.

### Conclusion

Unknown patients are an often marginalised, under represented and vulnerable subset of the Head Injury population. By describing the magnitude of the problem and the peculiar difficulties seen in treating these patients, we hope,

to bring these individuals to the foreground and restate that they require a particularly empathetic approach.

### References

1. Reinert MM, Bullock R. Clinical trials in head injury. *Neurol Res.* 1999.
2. Ahmad FU, Mahapatra AK, Mehta VS. Outcome of "unknown" head injury patients at a tertiary care neurosurgical centre. *Neurol India.* 2006.
3. Zaninotto ALC, Costa BT, Ferreira IS, French M, Paiva WS, Fregni F. Traumatic brain injury. In: *Neuromethods.* 2018.
4. Gardner AJ, Zafonte R. Neuroepidemiology of traumatic brain injury. In: *Handbook of Clinical Neurology.* 2016.
5. Topolovec-Vranic J, Schuler A, Gozdzik A, Somers J, Bourque PÉ, Frankish CJ, et al. The high burden of traumatic brain injury and comorbidities amongst homeless adults with mental illness. *J Psychiatr Res.* 2017.
6. Silverton CD, Dougherty P. High-Velocity. In: *Encyclopedia of Trauma Care.* 2015.
7. Bruns J, Hauser WA. The epidemiology of traumatic brain injury: a review. *Epilepsia.* 2003.
8. Isserman JD. Severe traumatic brain injury. In: *Practical Emergency Resuscitation and Critical Care.* 2013.
9. Miotto EC, Cinalli FZ, Serrao VT, Benute GG, Lucia MCS, Scaff M. Cognitive deficits in patients with mild to moderate traumatic brain injury. *Arq Neuropsiquiatr.* 2010;68(6):862-8.
10. Tsaousides T, Gordon W a. Cognitive rehabilitation following traumatic brain injury: assessment to treatment. *Mt Sinai J Med.* 2009;76(2):173-81.
11. Dikmen SS, Corrigan JD, Levin HS, MacHamer J, Stiers W, Weisskopf MG. Cognitive outcome following traumatic brain injury. *Journal of Head Trauma Rehabilitation.* 2009.



## Case Series on Vascular Malformations Presenting as Seizures

Pradeep B.<sup>1</sup>, Vignesh S.<sup>2</sup>, Raghavendran R.<sup>3</sup>

### Abstract

Intracranial vascular malformations, that includes arteriovenous malformations and cavernous malformations, are the most common cause of intracerebral hemorrhage in young adults. Seizures related to cavernous malformations seems to be attributable to surrounding hemosiderin deposition through leaky endothelial junctions. The estimated risk of occurrence of seizures in patients with vascular malformations is 1.5% per person-year of observation. Lesionectomy (excision of the vascular malformation) versus adjacent epileptogenic corticectomy studies have found lesionectomy enough to relieve the patient of the medically refractory epilepsy with class 1 Engels scale [4] outcome and is safer in eloquent areas of brain [3]. We present three interesting cases of vascular malformations with rare presentations and their surgical management. Vascular malformations presenting as refractory seizures is not a rare entity. Lesionectomy should be the management of choice in these patients in accessible lesions as it can lead to good outcome in terms of seizure outcome in these patients.

**Keywords:** Seizures; Arteriovenous malformations; lesionectomy.

### How to cite this article:

Pradeep B., Vignesh S., Raghavendran R. Case Series on Vascular Malformations Presenting as Seizures. *Int J Neurol Neurosurg.* 2019;11(2):145-153.

### Introduction

Intracranial vascular malformations, that includes arteriovenous malformations and cavernous malformations, are the most common cause of intracerebral hemorrhage in young adults.

Seizures related to cavernous malformations seems to be attributable to surrounding hemosiderin deposition through leaky endothelial junctions. The initial manifestations of intracranial vascular malformations depend on the underlying subtype. Seizures are the most common initial symptom of cavernous malformations, occurring as the initial feature in 34 to 70% of affected patients [2]. The estimated risk of occurrence of seizures in patients with vascular malformations is 1.5% per person-year of observation. Lesionectomy (excision of the vascular malformation) vs adjacent epileptogenic corticectomy studies have found lesionectomy enough to relieve the patient of the medically refractory epilepsy with class 1 Engels scale [4] outcome and is safer in eloquent areas of brain [3]. We present three interesting cases of vascular malformations with rare presentations and their surgical management.

**Author's Affiliation:** <sup>1,2</sup>Junior Resident, <sup>3</sup>Professor, Dept. of Neurosurgery, Institute of Neurosurgery, Madras Medical College, Park town, Chennai, Tamil Nadu, India 600003, India.

**Corresponding Author: Pradeep B.,** Junior Resident, Dept. of Neurosurgery, Institute of Neurosurgery, Madras Medical College, Park town, Chennai, Tamil Nadu, India 600003, India.

**E-mail:** [pradeepbalaji.krr@gmail.com](mailto:pradeepbalaji.krr@gmail.com)

**Received on 15.03.2019, Accepted on 16.04.2019**

## Case Series

### Case 1

A 30 year old female, presented with headache and formed visual hallucinations on and off seeing coloured butterflies in both eyes for 4 years. Psychiatric consulted for the same and was started on antipsychotics (SSRIs) for the same. Fields showed Right homonymous hemianopia by confrontation. Imaging showed Spetzler-Martin GRADE 3 arteriovenous malformation (Spetzler-Ponce class B) in left occipital cortex with feeders from Left posterior cerebral artery and Left middle cerebral artery and major draining vein into superior sagittal sinus with Type 4 intranidal aneurysm (Fig. 1(a)) (Fig. 1(b)). Left occipital craniotomy and total excision of arteriovenous malformation was done (Fig. 1(c)). Patient improved in her symptoms, discharged on 10<sup>th</sup> postoperative day. On 3<sup>rd</sup> month follow-up- free of the occipital lobe seizures (Engels outcome scale-Class 1), field deficits-improved.

### Case 2

A 15 year old male patient presented with headache for eight months, intracranial pressure type with seizures of GTCS semiology. Records of treatment showed posterior third ventricular space occupying lesion with obstructive hydrocephalus and right VP shunt done and Right Parietal

craniotomy and Transcortical approach was done without success. Patient continued to have episodes of seizures of same semiology. Imaging showed a pineal region Cavernoma (Fig. 2(a) and 2(b)).

Right parietal craniotomy upto midline was done with posterior interhemispheric approach (Fig. 3(a) and Fig. 3(b)) posterior to splenium of corpus callosum (retrocallosal) to reach the cavernoma which was microsurgically dissected and total excision done. Post operatively-boy was relieved of seizures (Engels class 1) and discharged on 15<sup>th</sup> postoperative day.

### Case 3

A 25 year old male patient, known case of seizure disorder for 10 years with partial seizures involving left upper limb presented with another episode- same semiology but with secondary generalisation 2 weeks back with MRI brain done, showing a Right Temporal Pial Arteriovenous fistula and was referred to our institute. Patient had bilateral proptosis and optic disc showed no papilloedema. On CT angiogram and DSA, patient had a right Temporal Pial Arteriovenous fistula with feeders from Right Middle cerebral artery and draining into the inferior anastomotic vein of Labbe and further into the Right Transverse-Sigmoid sinus junction. DSA also showed bilateral indirect Carotico-cavernous fistula fed by the Middle Meningel arteries (Figs. 4.(a)(b)(c)).

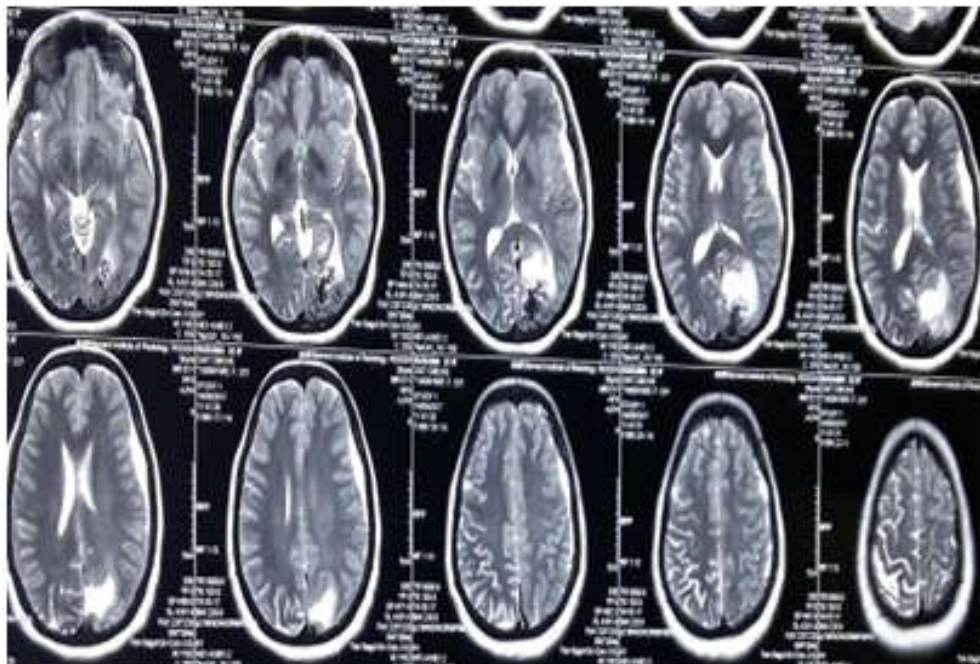
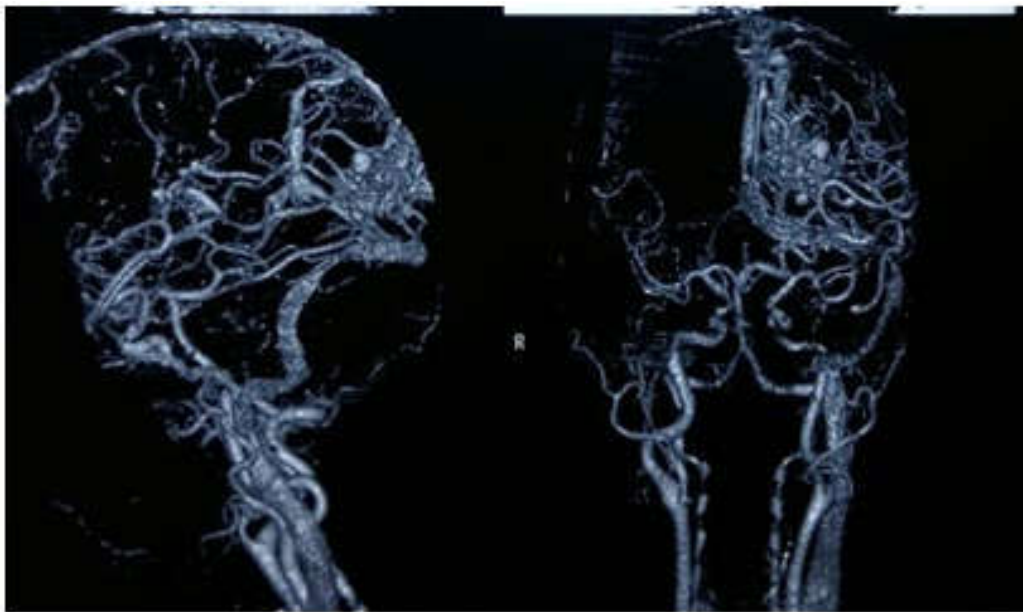

Fig. 1: Case Report 1 (a) T2 MRI showing arteriovenous malformation in left occipital lobe

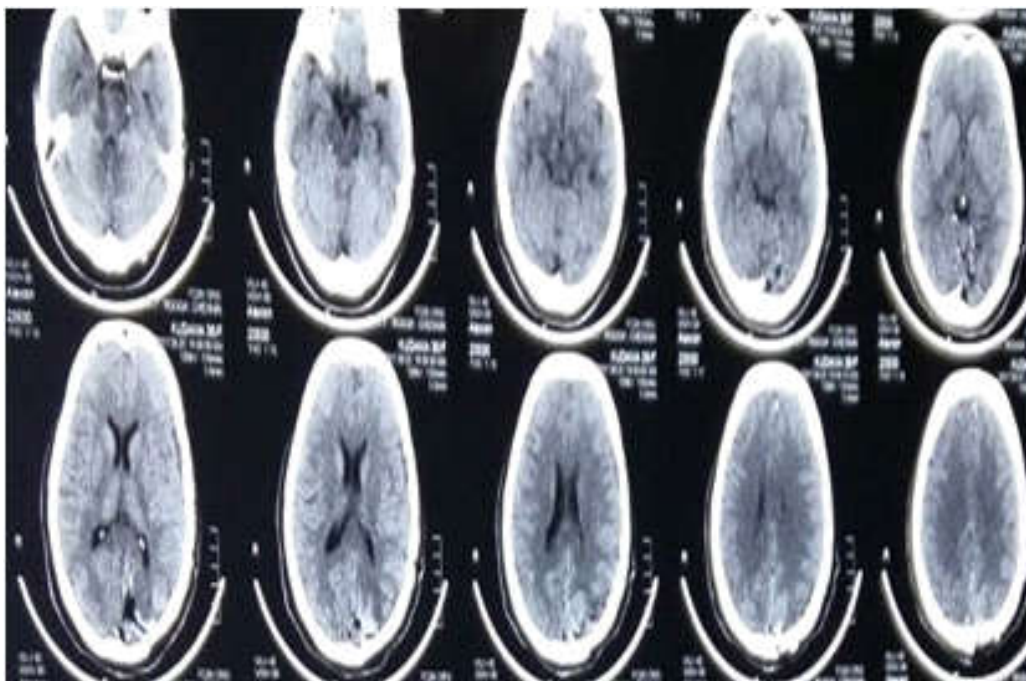
Pterional flap with Right Frontotemporal Craniotomy and Sylvian dissection (Fig. 5(a)) with clipping of two main feeders from superior and inferior divisions of middle cerebral artery and cauterisation of other smaller feeders done. On clipping the second major feeder, Arteriovenous fistula varix shrunk in size and decreased in

pulsation. It was followed leading to the major draining vein (vein of Labbe) and clipped (silver clips) close to sac and sac excised (Fig. 5(b)). Post operative CECT Brain showed total occlusion of Arteriovenous fistula (Fig. 5(c)).

Patient improved post operatively with CT Angiogram showing total occlusion of Fistula.



**Fig. 1(b):** CT Angiogram showing the arteriovenous malformation.



**Fig. 1(c):** Post operative CT showing total excision

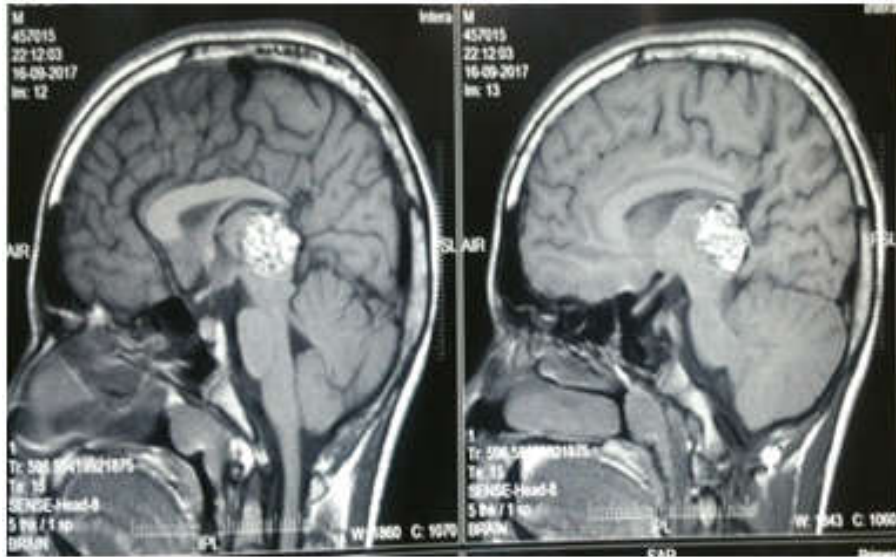


Fig. 2: Case Report 2: (a) T1 MRI showing Pineal Cavernoma.

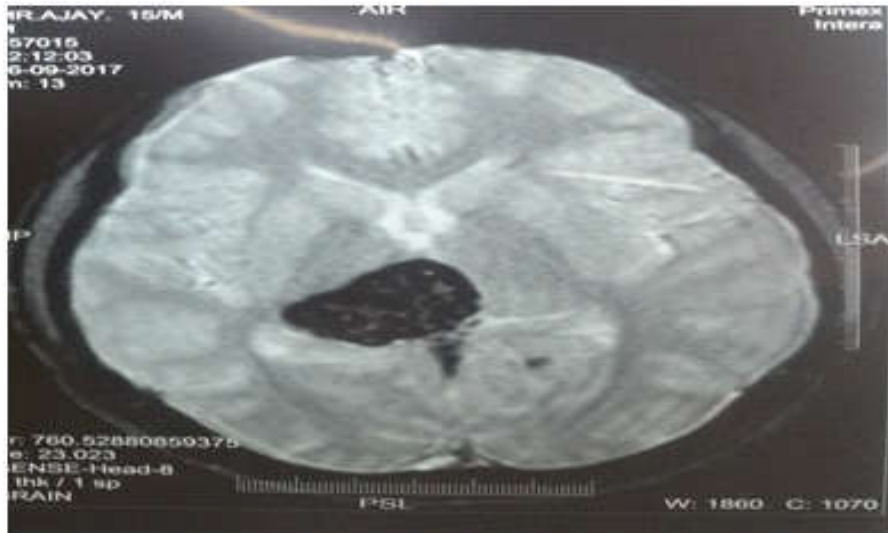


Fig. 2(b): SWI showing characteristic - Blooming

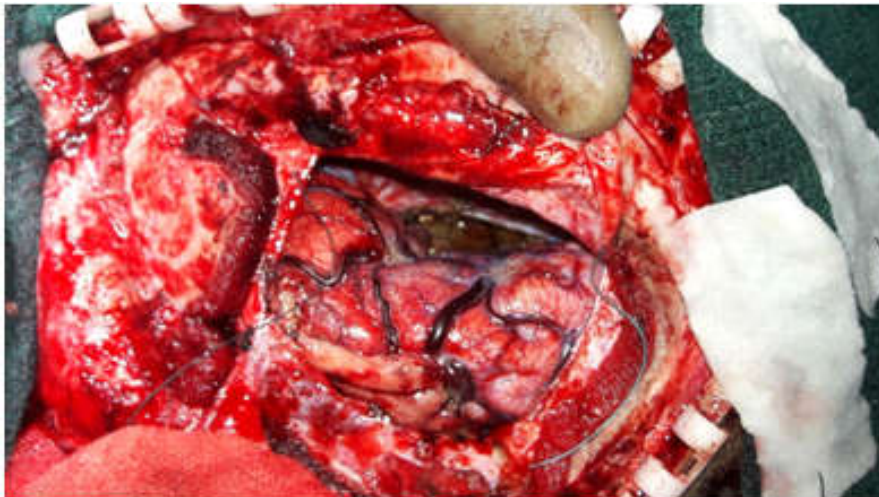


Fig. 3: Case Report 2 (a). Posterior interhemispheric retrocallosal approach.



Fig. 3(b): Resected Cavernoma specimen.

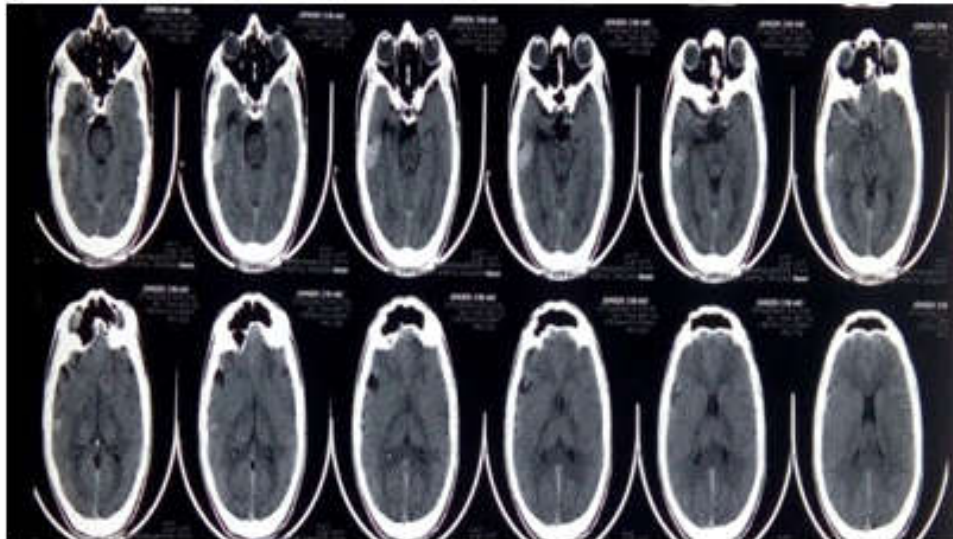


Fig. 4: Case Report 3: (a). CT showing the Right Temporal hyperdense arteriovenous fistula varix

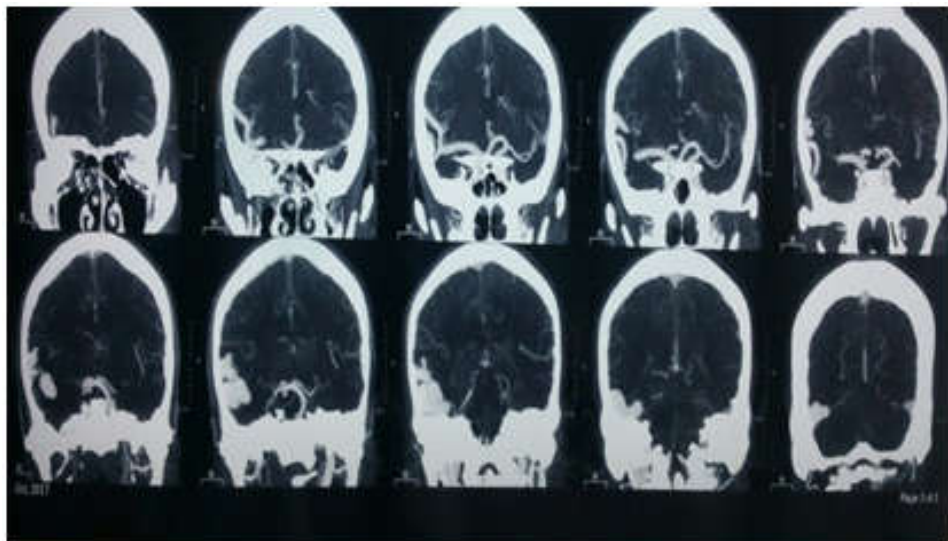
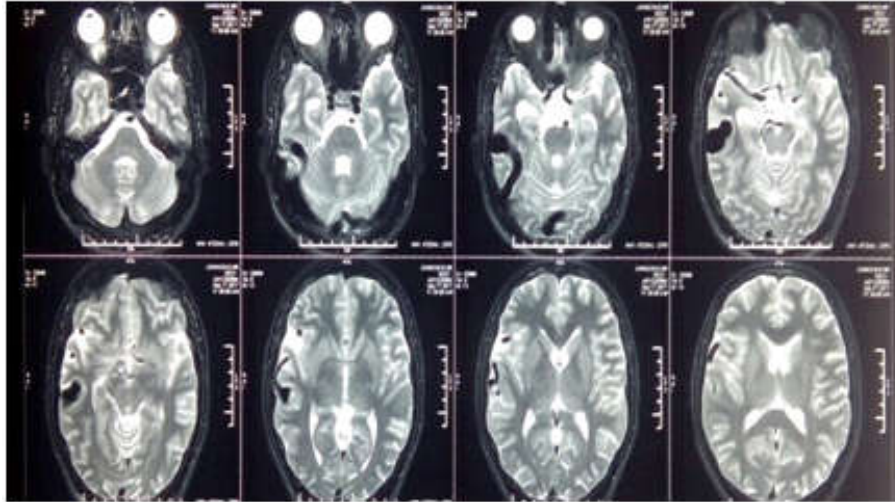
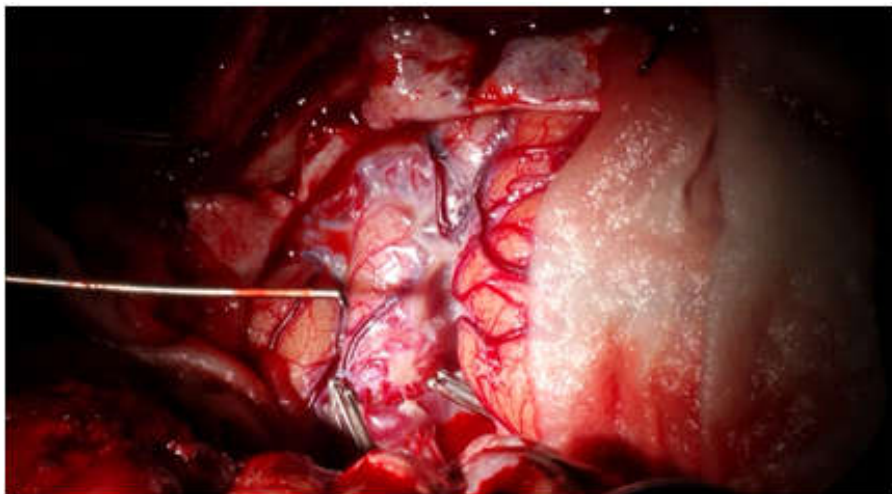


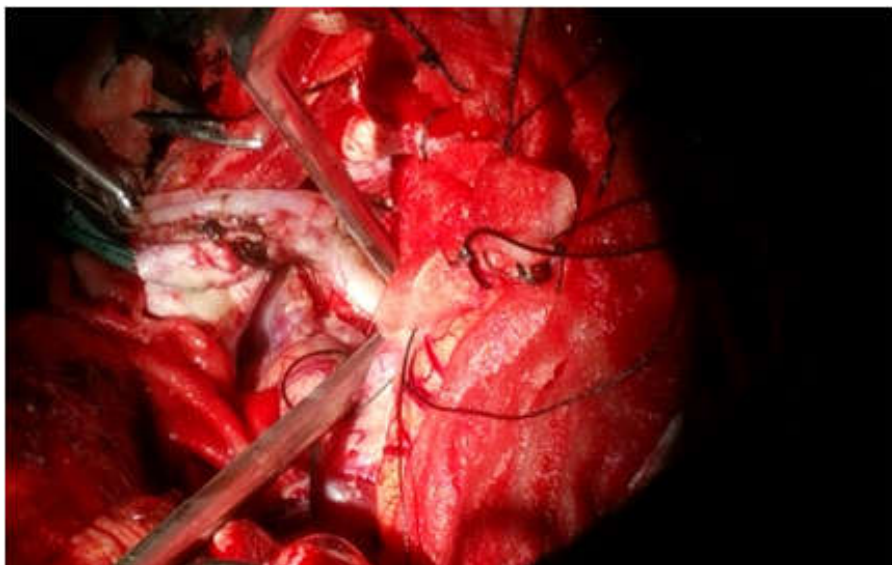
Fig. 4(b): CT Angiogram showing Pial Arteriovenous fistula with Right middle cerebral artery feeders and drainage into vein of Labbe.



**Fig. 4(c):** T2 MRI showing the Pial Arteriovenous fistula.



**Fig. 5:** Case report 3: (a) Intra operative picture showing Pial Arteriovenous fistula with sylvian dissection and clipping of feeders



**Fig. 5(b):** Intraoperative picture showing showing the varix dissected upto venous end.

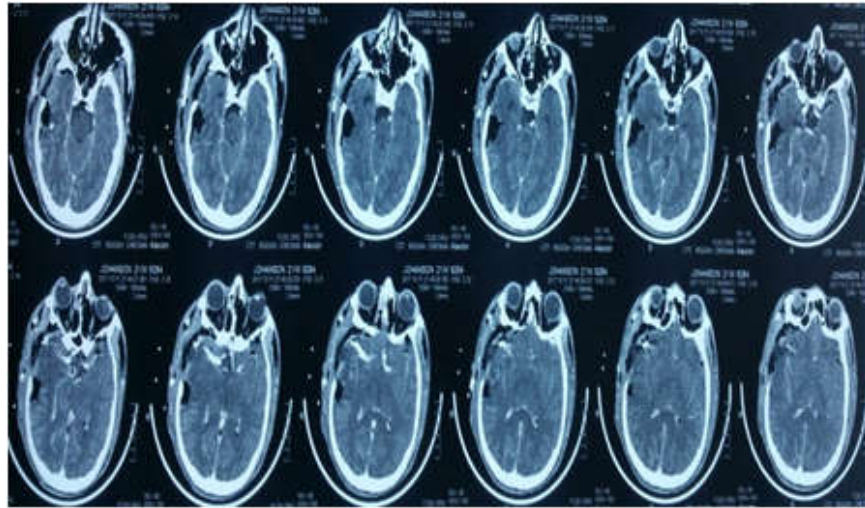


Fig. 5(c): Post operative CT showing total occlusion of Pial Arteriovenous fistula.

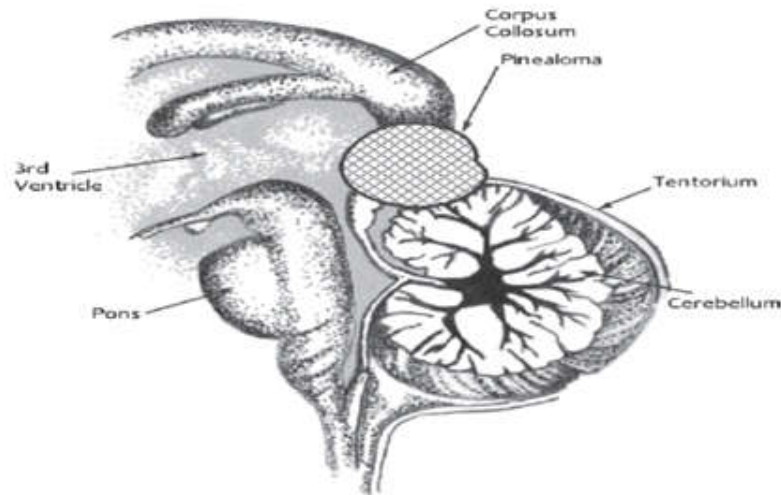


Fig. 6(a): Morphology of Pineal region lesion favourable to Retrocallosal approach (diagrammatic).

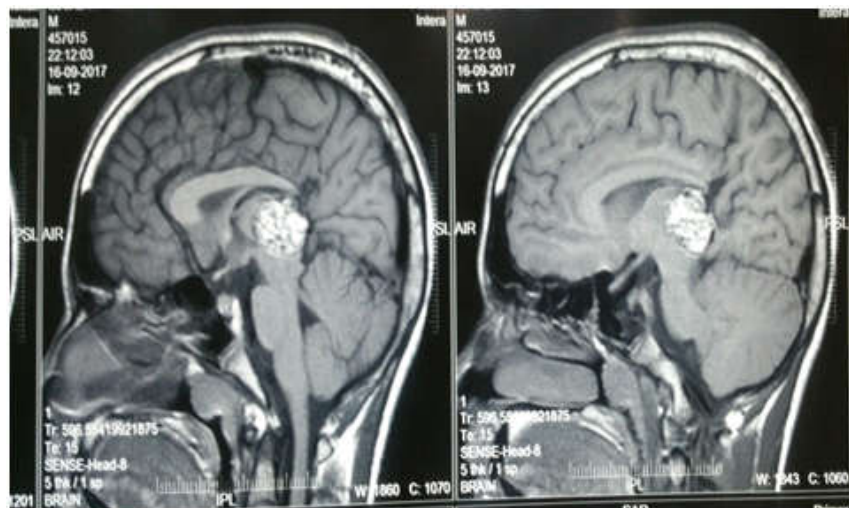


Fig. 6(b): MRI of Patient 2 with Pineal Cavernoma

**Table 1:** Shows region involved, semiology of seizures and pathology of lesion.

	Region involved	Seizure Semiology	Pathology of lesion
Patient 1	Left Occipital	Occipital	Arteriovenous malformation
Patient 2	Pineal	GTCS	Cavernoma
Patient 3	Right Temporal	Partial	Pial Arteriovenous malformation fistula

No increase in size noted in the bilateral indirect Caroticocavernous fistulas. Patient was discharged on 12<sup>th</sup> postoperative day. On 3<sup>rd</sup> month follow up, patient was relieved of seizures (Engels class 1). He is now on regular follow-up.

## Discussion

All three patients in this case series had varied presentations in respect to the site of lesion, seizure semiology and pathology of the vascular malformations. All three were treated with surgical excision of the lesion and had excellent recovery in terms of Epilepsy outcome (Table 1).

Usually patients with occipital lobe lesions will only have unformed hallucinations in the form of coloured blobs and flashes [15]. But in cases when Peristriate and Paraistriate cortices are involved patient may present with formed hallucinations [15] as in our case where patient had hallucinatory episodes of seeing butterflies.

Primary generalized seizure (GTCS) is more common in pineal region tumours [9]. Probably due to mass effect on the surrounding veins that affects normal perfusion, compressive effect on the quadrigeminal plate and the aqueduct of the midbrain, hemosiderin deposits or secretion disturbances of anticonvulsive agent melatonin can be involved in the pathogenesis of seizures. In our patient 2 also, presentation was that of GTCS semiology. Pineal cavernoma was morphologically favourable for a Retrocallosal Posterior interhemispheric approach (Figs. 6(a)(b)) and the patient being young, Callosal and Forniceal damage and deficits can be prevented by approaching posterior to splenium and not splitting it as in case of a standard Posterior interhemispheric approach and so is preferred in this patient.

Pial arteriovenous fistula (AVF) is an extremely rare intracranial vascular lesion, consistent of one or more arterial supply in direct connection to the venous drainage without intervening nidus, the key feature of arteriovenous malformation (AVM). From 1977 to 2009, only 112 cases have been reported in 43 reports that too mostly in pediatric age group [5,12]. It is believed to be a

result of abnormal embryological (missed-step) development of cerebrovasculature [5,6]. Younger age (<15 years old) are more likely to have varix in angiographic study [5]. The absence of varix do have significant correlation with haemorrhage. Younger patients are more likely to have symptom related to shunting effect; however, haemorrhage is the major presentation in older patients. In our patient, presentation was with refractory seizures though the patient was a young adult [5].

Syndromic association- Rendu Osler Weber syndrome, Hereditary Hemorrhagic Telangiectasia types 1 to 4. But no positive family history or other manifestations in our patient.

In our patient, bilateral cavernous sinus dural arteriovenous fistulas were present but were asymptomatic. So, only the pial arteriovenous fistula was treated and patient is on followup for the cavernous sinus dural arteriovenous fistulas.

There are case reports of Pial arteriovenous fistula, Pial arteriovenous malformation and dural arteriovenous fistulas presenting with bilateral proptosis due to stenosis or thrombosis of bilateral transverse sinus and venous reflux with dilatation of superior ophthalmic veins causing the proptosis [12,13]. But in our case both transverse sinuses were patent on DSA and the CSDAVFs are primary, between MMAs and draining into Cavernous sinus. To our knowledge, this is the first case being reported in the literature with Pial AVF with bilateral true indirect CCFs in the same patient that too an adult.

No standard guidelines as most experiences come from case reports and case series. Hoh et al. [15] have demonstrated a successful treatment by simply disconnecting the shunt using either surgical or endovascular technique.

Obliteration rate of 86.5% for endovascular treatment and 96.8% for surgical management has been recorded in literature [15].

Unfavorable angiographic features include drainage of the normal vein into the venous varix, multiple enpassage feeders draining into the fistula and normal cortical vessels arising close to the fistula [12]. These features do not necessarily mean a contraindication for embolization. They necessitate



modification of the technique to embolize the fistulous location precisely and if necessary to consider surgical disconnection. Surgical treatment could be difficult when the lesion is deep seated, in critical areas, obscured by large drainage vein, or small arteriovenous fistula.

Lesion being surgically accessible, varix being large and the indication being refractory epilepsy, we chose surgical excision over Endovascular management in this patient.

### Conclusion

Vascular malformations presenting as refractory seizures is not a rare entity. Lesionectomy should be the management of choice in these patients in accessible lesions as it can lead to good outcome in terms of seizure outcome in these patients.

### References

1. Theodore H Schwartz. Epilepsy Surgeons, Rather than Vascular Neurosurgeons, Should Operate on Cavernous malformations that Cause Seizures – A Modest Proposal. *Epilepsy Curr.* 2010 May;10(3): 59-60.
2. Van Gompel JJ, Rubio J, Cascino GD, Worrell GA, Meyer FB. J. Electrocorticography-Guided Resection of Temporal Cavernoma: Is Electrocorticography warranted and does It Alter the Surgical Approach?; *Neurosurg.* 2009;110(6):1179-1185.
3. Dodick DW, Cascino GD, Meyer FB. Vascular malformations and intractable epilepsy: outcome after surgical treatment. *Mayo Clin Proc.* 1994 Aug;69(8):741-5.
4. Engel J. *Surgical Treatment of Epilepsies*, 2<sup>nd</sup> Edition, Editor. Raven Press. 1993. Page 615.
5. Yang WH, Lu MS, Cheng YK, Wang TC. Pial arteriovenous fistula: a review of literature. *Br J Neurosurg.* 2011 Oct;25(5):580-5.
6. Anand Alurkar, Lakshmi Sudha, Prasanna Karanam, Suresh Nayak, Rajesh Kumar Ghanta. Intracranial Pial Arteriovenous Fistulae: Diagnosis and Treatment Techniques in Pediatric patients with Review of Literature. *J Clin Imaging Sci.* 2016; 6:2.
7. Laurence Davidson et al. Posterior interhemispheric retrocallosal approach to pineal region and posterior fossa lesions in a pediatric population, *Journal of Neurosurgery: Pediatrics.* 2011 May;7:527-33.
8. Behari S, Garg P, Jaiswal S, Nair A, Naval R, Jaiswal AK. Major surgical approaches to the posterior third ventricular region: A pictorial review, *Journal of Pediatric Neurosciences.* 2010;5(2):97-101. doi:10.4103/1817-1745.76093.
9. Hajnsek S, Paladino J, Gadze ZP, Nanković S, Mrak G, Lupret V. Clinical and neurophysiological changes in patients with pineal region expansions. *Coll Antropol.* 2013 Mar;37(1):35-40.
10. Jouibari MF, Zadeh MZ, Khadivi M, Khoshnevisan A, Moazzeni K, Abdollahzade S. Pial Arteriovenous Fistula with Giant Varices: Report of Two Cases with Good Surgical Outcome; *Journal of Cerebrovascular and Endovascular Neurosurgery.* 2014;16(2):98-103. doi:10.7461/jcen.2014.16.2.98.
11. Paramasivam S, Toma N, Niimi Y, et al. De novo development of dural arteriovenous fistula after endovascular embolization of pial arteriovenous fistula; *Journal of NeuroInterventional Surgery.* 2013 Jul;5(4):321-6. Published Online First. 17 April 2012. doi: 10.1136/neurintsurg-2012-010318.
12. Paramasivam S, Toma N, Niimi Y, et al. Development, clinical presentation and endovascular management of congenital intracranial pial arteriovenous fistulas, *Journal of NeuroInterventional Surgery.* 2012;33:1710-19. Published Online First: 19 February 2012. Doi: 10.1136/neurintsurg-2011-010241.
13. D Squirrell, P Puri et al. Anomalous venous drainage of a plexiform (pial) arteriovenous malformation mimicking an indirect caroticoavernous sinus fistula. *Br J Ophthalmol.* 2002 Jun;86(6):702-04.
14. Saligoudar P, Seshadri R, Pandey P. Rare presentation of pial arteriovenous malformations as proptosis: Case report and review of literature; *Neurol India.* 2013;61:200-1.
15. Adcock JE, Panayiotopoulos CP. Occipital lobe seizures and epilepsies. *J Clin Neurophysiol.* 2012; 29(5):397-407.
16. Hoh BL, Putman CM, Budzik RF, Ogilvy CS. Surgical and endovascular flow disconnection of intracranial pial single-channel arteriovenous fistulae. *Neurosurgery.* 2001;49:1351-63.

## Instructions to Authors

Submission to the journal must comply with the Guidelines for Authors.  
Non-compliant submission will be returned to the author for correction.

To access the online submission system and for the most up-to-date version of the Guide for Authors please visit:

<http://www.rfppl.co.in>

Technical problems or general questions on publishing with IJNNS are supported by Red Flower Publication Pvt. Ltd's Author Support team ([http://rfppl.co.in/article\\_submission\\_system.php?mid=5#](http://rfppl.co.in/article_submission_system.php?mid=5#))

Alternatively, please contact the Journal's Editorial Office for further assistance.

Editorial Manager  
Red Flower Publication Pvt. Ltd.  
48/41-42, DSIDC, Pocket-II  
Mayur Vihar Phase-I  
Delhi - 110 091(India)  
Mobile: 9821671871, Phone: 91-11-22754205, 45796900, 22756995  
E-mail: [author@rfppl.co.in](mailto:author@rfppl.co.in)

Manuscripts must be prepared in accordance with “Uniform requirements for Manuscripts submitted to Biomedical Journal” developed by international committee of medical Journal Editors

## Types of Manuscripts and Limits

Original articles: Up to 3000 words excluding references and abstract and up to 10 references.

Review articles: Up to 2500 words excluding references and abstract and up to 10 references.

Case reports: Up to 1000 words excluding references and abstract and up to 10 references.

## Online Submission of the Manuscripts

Articles can also be submitted online from [http://rfppl.co.in/customer\\_index.php](http://rfppl.co.in/customer_index.php).

1) First Page File: Prepare the title page, covering letter, acknowledgement, etc. using a word processor program. All information which can reveal your identity should be here. use text/rtf/doc/PDF files. Do not zip the files.

2) Article file: The main text of the article, beginning from Abstract till References (including tables) should be in this file. Do not include any information (such as acknowledgement, your name in page headers, etc.) in this file. Use text/rtf/doc/PDF files. Do not zip the files. Limit the file size to 400 Kb. Do not incorporate images in the file. If file size is large, graphs can be submitted as images separately without incorporating them in the article file to reduce the size of the file.

3) Images: Submit good quality color images. Each image should be less than 100 Kb in size. Size of the image can be reduced by decreasing the actual height and width of the images (keep up to 400 pixels or 3 inches). All image formats (jpeg, tiff, gif, bmp, png, eps etc.) are acceptable; jpeg is most suitable.

Legends: Legends for the figures/images should be included at the end of the article file.

If the manuscript is submitted online, the contributors' form and copyright transfer form has to be submitted in original with the signatures of all the contributors within two weeks from submission. Hard copies of the images (3 sets), for articles submitted online, should be sent to the journal office at the time of submission of a revised manuscript. Editorial office: Red Flower Publication Pvt. Ltd., 48/41-42, DSIDC, Pocket-II, Mayur Vihar Phase-I, Delhi - 110 091, India, Phone: 91-11-22754205, 45796900, 22756995. E-mail: [author@rfppl.co.in](mailto:author@rfppl.co.in). Submission page: [http://rfppl.co.in/article\\_submission\\_system.php?mid=5](http://rfppl.co.in/article_submission_system.php?mid=5).

## Preparation of the Manuscript

The text of observational and experimental articles should be divided into sections with the headings: Introduction, Methods, Results, Discussion, References, Tables, Figures, Figure legends, and Acknowledgment. Do not make subheadings in these sections.

## Title Page

The title page should carry

- 1) Type of manuscript (e.g. Original article, Review article, Case Report)
- 2) The title of the article, should be concise and informative;
- 3) Running title or short title not more than 50 characters;
- 4) The name by which each contributor is known (Last name, First name and initials of middle name), with his or her highest academic degree(s) and institutional affiliation;
- 5) The name of the department(s) and institution(s) to which the work should be attributed;
- 6) The name, address, phone numbers, facsimile numbers and e-mail address of the contributor responsible for correspondence about the manuscript; should be mentioned.
- 7) The total number of pages, total number of photographs and word counts separately for abstract and for the text (excluding the references and abstract);
- 8) Source(s) of support in the form of grants, equipment, drugs, or all of these;
- 9) Acknowledgement, if any; and
- 10) If the manuscript was presented as part at a meeting, the organization, place, and exact date on which it was read.

## Abstract Page

The second page should carry the full title of the manuscript and an abstract (of no more than 150 words for case reports, brief reports and 250 words for original articles). The abstract should be structured and state the Context (Background), Aims, Settings and Design, Methods and Materials, Statistical analysis used, Results and Conclusions. Below the abstract should provide 3 to 10 keywords.

## Introduction

State the background of the study and purpose of the study and summarize the rationale for the study or observation.

## Methods

The methods section should include only information that was available at the time the plan or protocol for the study was written such as study approach, design, type of sample, sample size, sampling technique, setting of the study, description of data collection tools and methods; all information obtained during the conduct of the study belongs in the Results section.

Reports of randomized clinical trials should be based on the CONSORT Statement (<http://www.consort-statement.org>). When reporting experiments on human subjects, indicate whether the procedures followed were in accordance with the ethical standards of the responsible committee on human experimentation (institutional or regional) and with the Helsinki Declaration of 1975, as revised in 2000 (available at [http://www.wma.net/e/policy/17-c\\_e.html](http://www.wma.net/e/policy/17-c_e.html)).

## Results

Present your results in logical sequence in the text, tables, and illustrations, giving the main or most important findings first. Do not repeat in the text all the data in the tables or illustrations; emphasize or summarize only important observations. Extra or supplementary materials and technical details can be placed in an appendix where it will be accessible but will not interrupt the flow of the text; alternatively, it can be published only in the electronic version of the journal.

## Discussion

Include summary of key findings (primary outcome measures, secondary outcome measures, results as they relate to a prior hypothesis); Strengths and limitations of the study (study question, study design, data collection, analysis and interpretation); Interpretation and implications in the context of the totality of evidence (is there a systematic review to refer to, if not, could one be reasonably done here and now?, What this study adds to the available evidence, effects on patient care and health policy, possible mechanisms)? Controversies raised by this study; and Future research directions (for this particular research collaboration, underlying mechanisms, clinical research). Do not repeat in detail data or other

material given in the Introduction or the Results section.

## References

List references in alphabetical order. Each listed reference should be cited in text (not in alphabetic order), and each text citation should be listed in the References section. Identify references in text, tables, and legends by Arabic numerals in square bracket (e.g. [10]). Please refer to ICMJE Guidelines ([http://www.nlm.nih.gov/bsd/uniform\\_requirements.html](http://www.nlm.nih.gov/bsd/uniform_requirements.html)) for more examples.

### Standard journal article

[1] Flink H, Tegelberg Å, Thörn M, Lagerlöf F. Effect of oral iron supplementation on unstimulated salivary flow rate: A randomized, double-blind, placebo-controlled trial. *J Oral Pathol Med* 2006; 35: 540-7.

[2] Twetman S, Axelsson S, Dahlgren H, Holm AK, Källestål C, Lagerlöf F, et al. Caries-preventive effect of fluoride toothpaste: A systematic review. *Acta Odontol Scand* 2003; 61: 347-55.

### Article in supplement or special issue

[3] Fleischer W, Reimer K. Povidone iodine antiseptics. State of the art. *Dermatology* 1997; 195 Suppl 2: 3-9.

### Corporate (collective) author

[4] American Academy of Periodontology. Sonic and ultrasonic scalers in periodontics. *J Periodontol* 2000; 71: 1792-801.

### Unpublished article

[5] Garoushi S, Lassila LV, Tezvergil A, Vallittu PK. Static and fatigue compression test for particulate filler composite resin with fiber-reinforced composite substructure. *Dent Mater* 2006.

### Personal author(s)

[6] Hosmer D, Lemeshow S. Applied logistic regression, 2nd edn. New York: Wiley-Interscience; 2000.

### Chapter in book

[7] Nauntofte B, Tenovou J, Lagerlöf F. Secretion and composition of saliva. In: Fejerskov O,

Kidd EAM, editors. Dental caries: The disease and its clinical management. Oxford: Blackwell Munksgaard; 2003. p. 7-27.

### No author given

[8] World Health Organization. Oral health surveys - basic methods, 4th edn. Geneva: World Health Organization; 1997.

### Reference from electronic media

[9] National Statistics Online – Trends in suicide by method in England and Wales, 1979-2001. [www.statistics.gov.uk/downloads/theme\\_health/HSQ20.pdf](http://www.statistics.gov.uk/downloads/theme_health/HSQ20.pdf) (accessed Jan 24, 2005): 7-18. Only verified references against the original documents should be cited. Authors are responsible for the accuracy and completeness of their references and for correct text citation. The number of reference should be kept limited to 20 in case of major communications and 10 for short communications.

More information about other reference types is available at [www.nlm.nih.gov/bsd/uniform\\_requirements.html](http://www.nlm.nih.gov/bsd/uniform_requirements.html), but observes some minor deviations (no full stop after journal title, no issue or date after volume, etc).

### Tables

Tables should be self-explanatory and should not duplicate textual material.

Tables with more than 10 columns and 25 rows are not acceptable.

Table numbers should be in Arabic numerals, consecutively in the order of their first citation in the text and supply a brief title for each.

Explain in footnotes all non-standard abbreviations that are used in each table.

For footnotes use the following symbols, in this sequence: \*, †, ‡, §,

### Illustrations (Figures)

Graphics files are welcome if supplied as Tiff, EPS, or PowerPoint files of minimum 1200x1600 pixel size. The minimum line weight for line art is 0.5 point for optimal printing.

When possible, please place symbol legends below the figure instead of to the side.

Original color figures can be printed in color at the editor's and publisher's discretion provided the author agrees to pay.

Type or print out legends (maximum 40 words, excluding the credit line) for illustrations using double spacing, with Arabic numerals corresponding to the illustrations.

### Sending a revised manuscript

While submitting a revised manuscript, contributors are requested to include, along with single copy of the final revised manuscript, a photocopy of the revised manuscript with the changes underlined in red and copy of the comments with the point to point clarification to each comment. The manuscript number should be written on each of these documents. If the manuscript is submitted online, the contributors' form and copyright transfer form has to be submitted in original with the signatures of all the contributors within two weeks of submission. Hard copies of images should be sent to the office of the journal. There is no need to send printed manuscript for articles submitted online.

### Reprints

Journal provides no free printed reprints, however a author copy is sent to the main author and additional copies are available on payment (ask to the journal office).

### Copyrights

The whole of the literary matter in the journal is copyright and cannot be reproduced without the written permission.

### Declaration

A declaration should be submitted stating that the manuscript represents valid work and that neither this manuscript nor one with substantially similar content under the present authorship has been published or is being considered for publication elsewhere and the authorship of this article will not be contested by any one whose name (s) is/are not listed here, and that the order of authorship as placed in the manuscript is final and accepted by the co-authors. Declarations should be signed by all the authors in the order in which they are mentioned in the original manuscript. Matters appearing in the Journal are covered by copyright but no objection will be made to their reproduction provided permission is obtained from the Editor prior to publication and due acknowledgment of the source is made.

### Approval of Ethics Committee

We need the Ethics committee approval letter from an Institutional ethical committee (IEC) or an institutional review board (IRB) to publish your Research article or author should submit a statement that the study does not require ethics approval along with evidence. The evidence could either be consent from patients is available and there are no ethics issues in the paper or a letter from an IRB stating that the study in question does not require ethics approval.

### Abbreviations

Standard abbreviations should be used and be spelt out when first used in the text. Abbreviations should not be used in the title or abstract.

### Checklist

- Manuscript Title
- Covering letter: Signed by all contributors
- Previous publication/ presentations mentioned, Source of funding mentioned
- Conflicts of interest disclosed

### Authors

- Middle name initials provided.
- Author for correspondence, with e-mail address provided.
- Number of contributors restricted as per the instructions.
- Identity not revealed in paper except title page (e.g.name of the institute in Methods, citing previous study as 'our study')

### Presentation and Format

- Double spacing
- Margins 2.5 cm from all four sides
- Title page contains all the desired information. Running title provided (not more than 50 characters)
- Abstract page contains the full title of the manuscript
- Abstract provided: Structured abstract provided for an original article.
- Key words provided (three or more)
- Introduction of 75-100 words
- Headings in title case (not ALL CAPITALS).

References cited in square brackets

- References according to the journal's instructions

### Language and grammar

- Uniformly American English
- Abbreviations spelt out in full for the first time. Numerals from 1 to 10 spelt out
- Numerals at the beginning of the sentence spelt out

### Tables and figures

- No repetition of data in tables and graphs and in text.
- Actual numbers from which graphs drawn, provided.
- Figures necessary and of good quality (color)
- Table and figure numbers in Arabic letters (not Roman).
- Labels pasted on back of the photographs (no names written)
- Figure legends provided (not more than 40 words)
- Patients' privacy maintained, (if not permission taken)
- Credit note for borrowed figures/tables provided
- Manuscript provided on a CDROM (with double spacing)

### Submitting the Manuscript

- Is the journal editor's contact information current?
- Is the cover letter included with the manuscript? Does the letter:
  1. Include the author's postal address, e-mail address, telephone number, and fax number for future correspondence?
  2. State that the manuscript is original, not previously published, and not under concurrent consideration elsewhere?
  3. Inform the journal editor of the existence of any similar published manuscripts written by the author?
  4. Mention any supplemental material you are submitting for the online version of your article. Contributors' Form (to be modified as applicable and one signed copy attached with the manuscript)

# REDKART.NET

(A product of RF Library Services (P) Limited)  
(Publications available for purchase: Journals, Books, Articles and Single issues)  
(Date range: 1967 to till date)

The Red Kart is an e-commerce and is a product of RF Library Services (P) Ltd. It covers a broad range of journals, Books, Articles, Single issues (print & Online-PDF) in English and Hindi languages. All these publications are in stock for immediate shipping and online access in case of online.

**Benefits of shopping online are better than conventional way of buying.**

1. Convenience.
2. Better prices.
3. More variety.
4. Fewer expenses.
5. No crowds.
6. Less compulsive shopping.
7. Buying old or unused items at lower prices.
8. Discreet purchases are easier.

URL: [www.redkart.net](http://www.redkart.net)

## Instructions to Authors

Submission to the journal must comply with the Guidelines for Authors.  
Non-compliant submission will be returned to the author for correction.

To access the online submission system and for the most up-to-date version of the Guide for Authors please visit:

<http://www.rfppl.co.in>

Technical problems or general questions on publishing with IJNNS are supported by Red Flower Publication Pvt. Ltd's Author Support team ([http://rfppl.co.in/article\\_submission\\_system.php?mid=5#](http://rfppl.co.in/article_submission_system.php?mid=5#))

Alternatively, please contact the Journal's Editorial Office for further assistance.

Editorial Manager  
Red Flower Publication Pvt. Ltd.  
48/41-42, DSIDC, Pocket-II  
Mayur Vihar Phase-I  
Delhi - 110 091(India)  
Mobile: 9821671871, Phone: 91-11-22754205, 45796900, 22756995  
E-mail: [author@rfppl.co.in](mailto:author@rfppl.co.in)